

# MEDICAL POLICY – 7.01.560


## Cervical Spine Surgeries: Discectomy, Laminectomy, and Fusion in Adults

BCBSA Ref. Policies: 7.01.145 & 7.01.146

Effective Date:	Dec. 5, 2024	RELATED MEDICAL POLICIES:
Last Revised:	Aug. 12, 2024	7.01.18 Automated Percutaneous and Percutaneous Endoscopic Discectomy
Replaces:	11.01.505 (renumbered)	7.01.72 Percutaneous Intradiscal Electrothermal Annuloplasty, Radiofrequency Annuloplasty, Biacuplasty, and Intraosseous Basivertebral Nerve Ablation
		7.01.87 Artificial Intervertebral Disc: Lumbar Spine
		7.01.108 Artificial Intervertebral Disc: Cervical Spine
		7.01.551 Lumbar Spine Decompression Surgery: Discectomy, Foraminotomy, Laminotomy, Laminectomy
		8.03.09 Vertebral Axial Decompression
		11.01.524 Site of Service: Select Surgical Procedures

Select a hyperlink below to be directed to that section.

- [POLICY CRITERIA](#) | [DOCUMENTATION REQUIREMENTS](#) | [CODING](#)
- [RELATED INFORMATION](#) | [EVIDENCE REVIEW](#) | [REFERENCES](#) | [APPENDIX](#) | [HISTORY](#)

 Clicking this icon returns you to the hyperlinks menu above.

### Introduction

There are several different types of neck (cervical) surgeries that can relieve pain that is caused by pressure on the spinal cord or nerves. Cervical fusion joins or fuses bones (vertebrae) in the neck. It is done through an incision either on the front or back of the neck. Laminectomy and laminotomy are two different surgeries that can be done on the lamina, which is the protective, bony covering that’s at the back of the spinal canal. A laminectomy is the full removal of the lamina. A laminotomy, which is also called a hemilaminectomy, is partial removal of the lamina. Sometimes the pain is caused by a disc that’s pressing on a nerve. In this case, surgery on the disc, called a discectomy, may be needed. This policy describes when cervical fusion, laminectomy, laminotomy, and discectomy may be considered medically necessary.

**Note:** The Introduction section is for your general knowledge and is not to be taken as policy coverage criteria. The rest of the policy uses specific words and concepts familiar to medical professionals. It is intended for providers. A provider can be a person, such as a doctor, nurse, psychologist, or dentist. A provider also can

be a place where medical care is given, like a hospital, clinic, or lab. This policy informs them about when a service may be covered.

## Policy Coverage Criteria

**Note: This policy only applies to adults age 19 and older.**

We will review for medical necessity this elective surgical procedure

**The surgical procedures subject to medical necessity review for site of service addressed in this policy are limited to:**

- **Single-level cervical decompression surgeries and single-level cervical fusions**

We will review for medical necessity these elective surgical procedures. We also will review the site of service for medical necessity for single-level cervical spinal fusions. Site of service is defined as the location where the surgical procedure is performed, such as an off campus-outpatient hospital or medical center, an on campus-outpatient hospital or medical center, an ambulatory surgical center, or an inpatient hospital or medical center.

Site of Service for Elective Surgical Procedures	Medical Necessity
<p><b>Medically necessary sites of service:</b></p> <ul style="list-style-type: none"> <li>• <b>Off campus-outpatient hospital/medical center</b></li> <li>• <b>On campus-outpatient hospital/medical center</b></li> <li>• <b>Ambulatory surgical center</b></li> </ul>	<p><b>Certain elective surgical procedures will be covered in the most appropriate, safe, and cost-effective site. These are the preferred medically necessary sites of service for certain elective surgical procedures.</b></p>
<p><b>Inpatient hospital/medical center</b></p>	<p><b>Certain elective surgical procedures will be covered in the most appropriate, safe, and cost-effective site. This site is considered medically necessary only when the individual has a clinical condition which puts him or her at increased risk for complications including any of the following (this list may not be all inclusive):</b></p> <ul style="list-style-type: none"> <li>• Anesthesia Risk <ul style="list-style-type: none"> <li>○ ASA classification III or higher (see <a href="#">definition</a>)</li> </ul> </li> </ul>



Site of Service for Elective Surgical Procedures	Medical Necessity
	<ul style="list-style-type: none"> <li>○ Personal history of complication of anesthesia</li> <li>○ Documentation of alcohol dependence or history of cocaine use</li> <li>○ Prolonged surgery (&gt;3 hours)</li> <li>● Cardiovascular Risk <ul style="list-style-type: none"> <li>○ Uncompensated chronic heart failure (<b>NYHA class</b> III or IV)</li> <li>○ Recent history of myocardial infarction (MI) (&lt;3 months)</li> <li>○ Poorly controlled, resistant hypertension*</li> <li>○ Recent history of cerebrovascular accident (&lt; 3 months)</li> <li>○ Increased risk for cardiac ischemia (drug eluting stent placed &lt; 1 year or angioplasty &lt;90 days)</li> <li>○ Symptomatic cardiac arrhythmia despite medication</li> <li>○ Significant valvular heart disease</li> </ul> </li> <li>● Liver Risk <ul style="list-style-type: none"> <li>○ Advanced liver disease (MELD Score &gt; 8)**</li> </ul> </li> <li>● Pulmonary Risk <ul style="list-style-type: none"> <li>○ Chronic obstructive pulmonary disease (COPD) (FEV1 &lt;50%)</li> <li>○ Poorly controlled asthma (FEV1 &lt;80% despite treatment)</li> <li>○ Moderate to severe obstructive sleep apnea (OSA)***</li> </ul> </li> <li>● Renal Risk <ul style="list-style-type: none"> <li>○ End stage renal disease (on dialysis)</li> </ul> </li> <li>● Other <ul style="list-style-type: none"> <li>○ Morbid obesity (BMI ≥ 50)</li> <li>○ Pregnancy</li> <li>○ Bleeding disorder (requiring replacement factor, blood products, or special infusion product [DDAVP**** does not meet this criterion])</li> <li>○ Anticipated need for transfusion(s)</li> </ul> </li> </ul> <p><b>Note:</b> * 3 or more drugs to control blood pressure  ** <a href="https://reference.medscape.com/calculator/meld-score-end-stage-liver-disease">https://reference.medscape.com/calculator/meld-score-end-stage-liver-disease</a>  *** Moderate-AHI ≥15 and ≤ 30, Severe-AHI ≥30  ****DDAVP-Deamino-Delta-D-Arginine Vasopressin (Desmopressin)</p>



Site of Service for Elective Surgical Procedures	Medical Necessity
Inpatient hospital/medical center	This site of service is considered NOT medically necessary for certain elective surgical procedures when the site of service criteria listed above in this policy are not met.

**Note: Requests for fusions of more than 2 levels must be reviewed by a medical director.**

Smoking within the 6 weeks just prior to scheduled surgery is a contraindication for **cervical spinal fusion** (see documentation requirements for **smoking cessation**).

This policy does not address the pre-operative cessation of smokeless/chewing/dipping/snuff tobacco or nicotine replacements such as electronic cigarettes (e-cigs), nicotine gum, nicotine lozenges and nicotine patches. No studies or literature were found that report the effect of these products on orthopedic surgical outcomes (see documentation requirements for **smoking cessation**).

See **Documentation Requirements** section for information that must be submitted for review.

Indications	Medical Necessity
<b>Anterior Cervical Fusion</b>	
<ul style="list-style-type: none"> <li>• Degenerative cervical spondylosis</li> <li>• Infection of cervical spine</li> <li>• Ossification of posterior longitudinal ligament (OPLL)</li> <li>• Posttraumatic cervical instability</li> <li>• Spine fracture and/or dislocation</li> <li>• Tumor of cervical spine</li> </ul>	<p><b>Anterior cervical fusion may be considered medically necessary when any ONE of the following conditions is present:</b></p> <ul style="list-style-type: none"> <li>• Degenerative cervical spondylosis with kyphosis causing cord compression</li> <li>• Infection of cervical spine requiring decompression or debridement</li> <li>• Ossification of posterior longitudinal ligament (OPLL) at 1 to 3 levels associated with myelopathy</li> <li>• Posttraumatic cervical instability (e.g., unstable anterior column fracture)</li> <li>• Spine fracture and/or dislocation (associated with mechanical instability), locked facets, or displaced fracture fragment</li> <li>• Tumor of cervical spine causing pathologic fracture, cord compression, or instability</li> </ul>



Indications	Medical Necessity
<p><b>Cervical radiculopathy</b></p>	<p><b>Anterior cervical fusion may be considered medically necessary for cervical radiculopathy when ALL of the following criteria are met:</b></p> <ul style="list-style-type: none"> <li>• The individual has unremitting radicular pain or progressive weakness secondary to nerve root compression.</li> </ul> <p><b>AND</b></p> <ul style="list-style-type: none"> <li>• Symptoms have been unresponsive to at least 6 weeks of conservative nonsurgical therapy, including <b>ALL</b> of the following: <ul style="list-style-type: none"> <li>○ Use of prescription strength analgesics for several weeks at a dose sufficient to induce a therapeutic response <ul style="list-style-type: none"> <li>▪ Analgesics should include anti-inflammatory medications with or without adjunctive medications such as nerve membrane stabilizers or muscle relaxants (if not contraindicated)</li> </ul> </li> <li>○ Physical therapy</li> <li>○ Evaluation and appropriate management of associated cognitive, behavioral or addiction issues when present</li> </ul> </li> </ul> <p><b>AND</b></p> <ul style="list-style-type: none"> <li>• A cervical spine MRI or CT scan with myelogram within the past 12 months demonstrates spinal stenosis or nerve root compression at the same level as the symptoms and physical exam findings</li> </ul>
<p><b>Spondylotic myelopathy</b></p>	<p><b>Anterior cervical fusion may be considered medically necessary for treatment of spondylotic myelopathy when ALL of the following criteria are met:</b></p> <ul style="list-style-type: none"> <li>• Signs or symptoms of myelopathy are present as indicated by <b>one or more</b> of the following: <ul style="list-style-type: none"> <li>○ Upper limb weakness in more than a single nerve root distribution</li> <li>○ Lower limb weakness</li> <li>○ Loss of dexterity (e.g., clumsiness of hands)</li> <li>○ Bowel or bladder incontinence</li> <li>○ Frequent falls</li> <li>○ Hyperreflexia</li> <li>○ Hoffmann sign</li> <li>○ Increased extremity muscle tone or spasticity</li> </ul> </li> </ul>



Indications	Medical Necessity
	<ul style="list-style-type: none"> <li>○ Gait abnormality</li> <li>○ Positive Babinski sign</li> </ul> <p><b>AND</b></p> <ul style="list-style-type: none"> <li>• A cervical spine MRI or CT scan with myelogram within the past 12 months demonstrates spinal cord compression corresponding to symptoms and physical exam findings due to <b>one or more</b> of the following: <ul style="list-style-type: none"> <li>○ Herniated disk</li> <li>○ Osteophyte</li> <li>○ Ossification of the posterior longitudinal ligament</li> </ul> </li> </ul>
<b>Cervical pseudarthrosis</b>	<p><b>Anterior cervical fusion may be considered medically necessary for symptomatic cervical pseudarthrosis (failed union) when ALL of the following criteria are met:</b></p> <ul style="list-style-type: none"> <li>• Radiographic evidence of hardware failure (e.g., fracture or displacement) is present</li> </ul> <p><b>OR</b></p> <ul style="list-style-type: none"> <li>• Axial neck pain corresponds to the level of the pseudoarthrosis and is unresponsive to at least 6 weeks of conservative nonsurgical therapy, including <b>ALL</b> of the following: <ul style="list-style-type: none"> <li>○ Use of prescription strength analgesics for several weeks at a dose sufficient to induce a therapeutic response <ul style="list-style-type: none"> <li>▪ Analgesics should include anti-inflammatory medications with or without adjunctive medications such as nerve membrane stabilizers or muscle relaxants (if not contraindicated)</li> </ul> </li> <li>○ Physical therapy</li> <li>○ Evaluation and appropriate management of associated cognitive, behavioral or addiction issues when present</li> </ul> </li> </ul> <p><b>AND</b></p> <ul style="list-style-type: none"> <li>• A cervical spine MRI or CT scan after 12 months since prior spinal fusion demonstrates non-union at the same level as the symptoms and physical exam findings</li> </ul>
<b>Degenerative spinal segment</b>	<p><b>Anterior cervical fusion may be considered medically necessary for a degenerative spinal segment adjacent to a prior decompressive or fusion procedure when 1 or more of the following criteria are met:</b></p>



Indications	Medical Necessity
	<ul style="list-style-type: none"> <li>• Symptomatic myelopathy corresponding clinically to an adjacent level</li> </ul> <p><b>OR</b></p> <ul style="list-style-type: none"> <li>• Symptomatic radiculopathy corresponding clinically to an adjacent level <b>AND</b> unresponsive to at least 6 weeks of conservative nonsurgical therapy, including <b>ALL</b> of the following: <ul style="list-style-type: none"> <li>○ Use of prescription strength analgesics for several weeks at a dose sufficient to induce a therapeutic response <ul style="list-style-type: none"> <li>▪ Analgesics should include anti-inflammatory medications with or without adjunctive medications such as nerve membrane stabilizers or muscle relaxants (if not contraindicated)</li> </ul> </li> <li>○ Physical therapy</li> <li>○ Evaluation and appropriate management of associated cognitive, behavioral or addiction issues when present</li> </ul> </li> </ul> <p><b>AND</b></p> <ul style="list-style-type: none"> <li>• A cervical spine MRI or CT scan with myelogram within the past 12 months demonstrates spinal stenosis or nerve root compression at the same level as the symptoms and physical exam findings</li> </ul>
<b>Cervical spine injury</b>	<p><b>Anterior cervical fusion may be considered medically necessary for treatment of a cervical spine injury (e.g., trauma) when ALL of the following criteria are met:</b></p> <ul style="list-style-type: none"> <li>• Acutely symptomatic cervical radiculopathy or myelopathy is present</li> <li>• MRI or other neuroimaging finding (e.g., cord compression, root compression) done within the past 12 months demonstrates pathologic anatomy corresponding to symptoms</li> </ul>
<b>Revision surgery</b>	<p><b>Cervical spine revision surgery may be considered medically necessary for implant/instrumentation failure demonstrated on imaging showing malposition or other evidence of failure (e.g., dislocation/subluxation, vertebral body fracture, hardware breakage)</b></p>
<b>Posterior Cervical Fusion</b>	



Indications	Medical Necessity
<p><b>As listed</b></p>	<p><b>Posterior cervical fusion may be considered medically necessary when any ONE of the following conditions is present:</b></p> <ul style="list-style-type: none"> <li>• Atlas and axis fractures</li> <li>• Bilateral locked facets</li> <li>• Cervical instability in individual with Down syndrome</li> <li>• Cervical instability in skeletal dysplasia or connective tissue disorders</li> <li>• Disruption of posterior ligamentous structures</li> <li>• Facet fractures with dislocation</li> <li>• Implant/instrumentation failure demonstrated on imaging showing malposition or other evidence of failure (e.g., dislocation/subluxation, vertebral body fracture, hardware breakage)</li> <li>• Infection of cervical spine requiring decompression or debridement</li> <li>• Klippel-Feil syndrome</li> <li>• Ossification of posterior longitudinal ligament without kyphosis with associated myelopathy</li> <li>• Part of stabilization procedure with corpectomy, laminectomy, or other procedure at cervicothoracic junction (e.g., C7 and T1)</li> <li>• Part of stabilization procedure with laminectomy (e.g., at C2)</li> <li>• Posttraumatic cervical instability</li> <li>• Subluxation and cord compression in rheumatoid arthritis</li> <li>• Tumor of cervical spine causing pathologic fracture, cord compression, or instability</li> </ul>
<p><b>Multilevel spondylotic myelopathy</b></p>	<p><b>Posterior cervical fusion may be considered medically necessary for the treatment of multilevel spondylotic myelopathy without kyphosis when ALL of the following criteria are met:</b></p> <ul style="list-style-type: none"> <li>• Signs or symptoms of myelopathy are present as indicated by <b>one or more</b> of the following: <ul style="list-style-type: none"> <li>○ Upper limb weakness in more than a single nerve root distribution</li> <li>○ Lower limb weakness</li> <li>○ Loss of dexterity (e.g., clumsiness of hands)</li> <li>○ Bowel or bladder incontinence</li> </ul> </li> </ul>





Indications	Medical Necessity
	<ul style="list-style-type: none"> <li>○ Frequent falls</li> <li>○ Hyperreflexia</li> <li>○ Hoffman sign</li> <li>○ Increased muscle tone or spasticity</li> <li>○ Gait abnormality</li> <li>○ Positive Babinski sign</li> </ul> <p><b>AND</b></p> <ul style="list-style-type: none"> <li>● MRI or other neuroimaging finding done within the past 12 months correlates with clinical signs and symptoms and demonstrates cord compression due to <b>one or more</b> of the following: <ul style="list-style-type: none"> <li>○ Herniated disk</li> <li>○ Osteophyte</li> </ul> </li> </ul>
<p><b>Symptomatic unstable cervical spondylosis</b></p>	<p><b>Posterior cervical fusion may be considered medically necessary for symptomatic unstable cervical spondylosis with radiographic findings that include one or more of the following:</b></p> <ul style="list-style-type: none"> <li>● Subluxation of more than 3.5 mm on static lateral views</li> <li>● Sagittal plane angulation of more than 11 degrees between adjacent segments</li> <li>● More than 4 mm of motion (subluxation) on dynamic views</li> </ul>
<p><b>Cervical pseudarthrosis</b></p>	<p><b>Posterior cervical fusion may be considered medically necessary for cervical pseudoarthrosis when ALL of the following criteria are met:</b></p> <ul style="list-style-type: none"> <li>● Radiographic evidence of hardware failure (e.g., fracture or displacement) is present</li> </ul> <p><b>OR</b></p> <ul style="list-style-type: none"> <li>● Axial neck pain corresponds to the level of the pseudoarthrosis and is unresponsive to at least 6 weeks of conservative nonsurgical therapy including <b>ALL</b> of the following: <ul style="list-style-type: none"> <li>○ Use of prescription strength analgesics for several weeks at a dose sufficient to induce a therapeutic response <ul style="list-style-type: none"> <li>▪ Analgesics should include anti-inflammatory medications with or without adjunctive medications such as nerve membrane stabilizers or muscle relaxants (if not contraindicated)</li> </ul> </li> <li>○ Physical therapy</li> </ul> </li> </ul>



Indications	Medical Necessity
	<ul style="list-style-type: none"> <li>○ Evaluation and appropriate management of associated cognitive, behavioral or addiction issues when present</li> </ul> <p><b>AND</b></p> <ul style="list-style-type: none"> <li>● A cervical spine MRI or CT scan after 12 months since prior spinal fusion demonstrates non-union at the same level as the symptoms and physical exam findings</li> </ul>
<b>Cervical spine injury</b>	<p><b>Posterior cervical fusion may be considered medically necessary for treatment of a cervical spine injury (e.g., trauma), when ALL of the following criteria are met:</b></p> <ul style="list-style-type: none"> <li>● Acutely symptomatic cervical radiculopathy or myelopathy is present</li> <li>● MRI or other neuroimaging finding (e.g., cord compression, root compression) done within the past 12 months demonstrates pathologic anatomy corresponding to symptoms</li> </ul>
<b>Cervical Discectomy</b>	
<b>Cervical discectomy</b>	<p><b>Cervical discectomy* may be considered medically necessary for the treatment of a cervical herniated disc when All of the following criteria are met:</b></p> <ul style="list-style-type: none"> <li>● Signs and symptoms of radiculopathy and/or myelopathy are present, such as <b>one or more</b> of the following: (see <a href="#">Appendix</a>) <ul style="list-style-type: none"> <li>○ Pain that radiates into the shoulder, down the arms to the hands</li> <li>○ Numbness and tingling in a dermatomal distribution</li> <li>○ Muscular weakness in a pattern associated with spinal nerve root compression</li> <li>○ Increased or abnormal reflexes corresponding to affected nerve root level</li> <li>○ Loss of sensation in a dermatomal pattern</li> </ul> </li> </ul> <p><b>AND</b></p> <ul style="list-style-type: none"> <li>● <b>One</b> of the following clinical presentations is present: <ul style="list-style-type: none"> <li>○ Rapidly progressing neurologic deficits; <b>OR</b></li> <li>○ Persistent debilitating neck, back, or arm pain; <b>OR</b></li> <li>○ Persistent or progressive symptoms of myelopathy are unresponsive to at least 6 weeks of conservative nonsurgical therapy, including <b>ALL</b> of the following:</li> </ul> </li> </ul>



Indications	Medical Necessity
	<ul style="list-style-type: none"> <li>▪ Use of prescription strength analgesics for several weeks at a dose sufficient to induce a therapeutic response               <ul style="list-style-type: none"> <li>▫ Analgesics should include anti-inflammatory medications with or without adjunctive medications such as nerve membrane stabilizers or muscle relaxants (if not contraindicated)</li> </ul> </li> <li>▪ Physical therapy</li> <li>▪ Evaluation and appropriate management of associated cognitive, behavioral or addiction issues when present</li> </ul> <p><b>AND</b></p> <ul style="list-style-type: none"> <li>○ Documentation of nerve root compression on imaging (MRI or CT) at a level that corresponds with the individual's symptoms.</li> </ul> <p><b>Cervical discectomy is considered not medically necessary for the treatment of a cervical herniated disc when the above criteria are not met.</b></p> <p><b>Note:</b> *Cervical discectomy refers to open anterior cervical discectomy (with or without fusion) or minimally invasive posterior cervical discectomy/foraminotomy</p>
<b>Cervical Laminectomy</b>	
<b>As listed</b>	<p><b>Cervical laminectomy may be considered medically necessary when ANY of the following conditions are present:</b></p> <ul style="list-style-type: none"> <li>• Spinal fracture, dislocation, locked facets, or displaced fracture fragment confirmed by imaging studies (e.g., CT or MRI)</li> <li>• Spinal infection confirmed by imaging studies (e.g., CT or MRI)</li> <li>• Spinal tumor confirmed by imaging studies (e.g., CT or MRI)</li> </ul>
<b>Cervical laminectomy</b>	<p><b>Cervical laminectomy may be considered medically necessary for the treatment of spinal stenosis (with or without spondylolisthesis), or other causes of spinal cord or nerve root compression (such as ossification of the posterior longitudinal ligament or the yellow ligament or ligamentum flavum hypertrophy) when ALL of the following criteria are met:</b></p>



Indications	Medical Necessity
	<ul style="list-style-type: none"> <li>• Signs and symptoms that meet at least <b>ONE</b> of the following criteria: <ul style="list-style-type: none"> <li>○ Rapidly progressing neurologic deficits; <b>OR</b></li> <li>○ Persistent debilitating pain that is unresponsive to at least 6 weeks of conservative nonsurgical therapy, including <b>ALL</b> of the following: <ul style="list-style-type: none"> <li>▪ Use of prescription strength analgesics for several weeks at a dose sufficient to induce a therapeutic response <ul style="list-style-type: none"> <li>▫ Analgesics should include anti-inflammatory medications with or without adjunctive medications such as nerve membrane stabilizers or muscle relaxants (if not contraindicated)</li> </ul> </li> <li>▪ Physical therapy</li> <li>▪ Evaluation and appropriate management of associated cognitive, behavioral or addiction issues when present</li> </ul> </li> </ul> </li> </ul> <p><b>OR</b></p> <ul style="list-style-type: none"> <li>○ Signs and symptoms of cervical myelopathy or cord compression (with or without radiculopathy) including any of the following: <ul style="list-style-type: none"> <li>▪ Difficulty with fine movements of the hand and upper extremity</li> <li>▪ Incoordination of the hand and upper extremity</li> <li>▪ Atrophy of the thenar (thumb muscle) and hypothenar (little finger muscle) eminence</li> <li>▪ Diffuse hyperreflexia and bilateral Babinski responses</li> <li>▪ Decreased sensation, vibratory response, and proprioception at a level of C5 or below</li> <li>▪ Inability to perform tandem walk</li> <li>▪ Bowel and bladder incontinence</li> </ul> </li> </ul> <p><b>AND</b></p> <ul style="list-style-type: none"> <li>• MRI or other neuroimaging finding (e.g., spinal cord compression, nerve root compression or myelographic changes) done within the past 12 months demonstrates pathologic anatomy corresponding to symptoms</li> </ul>



## Documentation Requirements

**The following information must be submitted to ensure an accurate, expeditious, and complete review for cervical spinal fusion, cervical discectomy or cervical laminectomy surgery:**

- Specific procedures requested with related procedure/diagnosis codes and identification of disc level(s) for surgery
- Office notes that include a current history and physical exam
- Clinical notes document the individual has been evaluated at least twice by a physician(s) before submitting a request for surgery (except in cases of malignancy, trauma, infection or rapidly progressive neurologic symptoms)
- Detailed documentation of extent and response to conservative therapy, if applicable, including outcomes of any procedural interventions, medication use and physical therapy/physiatrist notes
- Documentation of current smoking status, and a written statement that the individual was non-smoking for the 6 weeks prior to scheduled (non-emergent) surgery (not applicable to emergent surgery). See [smoking cessation](#) definition.
- Copy of radiologist's report(s) for diagnostic imaging (MRIs, CTs, etc.) completed within the past 12 months. Imaging must be performed and read by an independent radiologist. If discrepancies should arise in the interpretation of the imaging, the radiologist report will supersede

## Coding

Code	Description
<b>CPT</b>	
22551	Arthrodesis, anterior interbody, including disc space preparation, discectomy, osteophylectomy and decompression of spinal cord and/or nerve roots; cervical below C2
22552	Arthrodesis, anterior interbody, including disc space preparation, discectomy, osteophylectomy and decompression of spinal cord and/or nerve roots; cervical below C2, each additional interspace (List separately in addition to code for separate procedure)
22554	Arthrodesis, anterior interbody technique, including minimal discectomy to prepare interspace (other than for decompression); cervical below C2



Code	Description
22585	Arthrodesis, anterior interbody technique, including minimal discectomy to prepare interspace (other than for decompression); each additional interspace (List separately in addition to code for primary procedure)
22600	Arthrodesis, posterior or posterolateral technique, single interspace; cervical below C2 segment
22614	Arthrodesis, posterior or posterolateral technique, single interspace; each additional interspace (List separately in addition to code for primary procedure)
63001	Laminectomy with exploration and/or decompression of spinal cord and/or cauda equina, without facetectomy, foraminotomy or discectomy (eg, spinal stenosis), 1 or 2 vertebral segments; cervical
63015	Laminectomy with exploration and/or decompression of spinal cord and/or cauda equina, without facetectomy, foraminotomy or discectomy (eg, spinal stenosis), more than 2 vertebral segments; cervical
63020	Laminotomy (hemilaminectomy), with decompression of nerve root(s), including partial facetectomy, foraminotomy and/or excision of herniated intervertebral disc; 1 interspace, cervical
63040	Laminotomy (hemilaminectomy), with decompression of nerve root(s), including partial facetectomy, foraminotomy and/or excision of herniated intervertebral disc, reexploration, single interspace; cervical
63043	Laminotomy (hemilaminectomy), with decompression of nerve root(s), including partial facetectomy, foraminotomy and/or excision of herniated intervertebral disc, reexploration, single interspace; each additional cervical interspace (List separately in addition to code for primary procedure)
63045	Laminectomy, facetectomy and foraminotomy (unilateral or bilateral with decompression of spinal cord, cauda equina and/or nerve root[s], [e.g., spinal or lateral recess stenosis]), single vertebral segment; cervical
63048	Laminectomy, facetectomy and foraminotomy (unilateral or bilateral with decompression of spinal cord, cauda equina and/or nerve root[s], [eg, spinal or lateral recess stenosis]), single vertebral segment; each additional vertebral segment, cervical, thoracic, or lumbar (List separately in addition to code for primary procedure)
63050	Laminoplasty, cervical, with decompression of the spinal cord, 2 or more vertebral segments;
63051	Laminoplasty, cervical, with decompression of the spinal cord, 2 or more vertebral segments; with reconstruction of the posterior bony elements (including the application of bridging bone graft and non-segmental fixation devices [eg, wire, suture, mini-plates], when performed)
63075	Discectomy, anterior, with decompression of spinal cord and/or nerve root(s), including osteophyctomy; cervical, single interspace



Code	Description
63076	Discectomy, anterior, with decompression of spinal cord and/or nerve root(s), including osteophylectomy; cervical, each additional interspace (List separately in addition to code for primary procedure)
63081	Vertebral corpectomy (vertebral body resection), partial or complete, anterior approach with decompression of spinal cord and/or nerve root(s); cervical, single segment
63265	Laminectomy for excision or evacuation of intraspinal lesion other than neoplasm, extradural; cervical

**Note:** CPT codes, descriptions and materials are copyrighted by the American Medical Association (AMA). HCPCS codes, descriptions and materials are copyrighted by Centers for Medicare Services (CMS).

## Related Information

### Definition of Terms

**Positive Babinski sign:** A reflex response consisting of extension of the big toe when the sole of the foot is stroked.

**Cervical myelopathy:** The loss of function in the upper and lower extremities due to compression of the spinal cord within the neck.

**Cervical radiculopathy:** Persistent neck pain that radiates into the shoulder/arm in a dermatomal/single nerve pattern, or progressive weakness caused by irritation or injury near the root of a spinal nerve in the neck. The North American Spine Society (NASS) describes the most common clinical findings as arm pain, neck pain, scapular or periscapular pain, paresthesias, numbness and sensory changes, weakness, or abnormal deep tendon reflexes in the arm.

**Cervical spondylosis:** Abnormal wear of the cartilage and bones in the cervical vertebrae. This includes the discs or cushions between the neck vertebrae and the joints between the bones of the cervical spine. May result in bone spurs.

**Dermatome/dermatomal:** Each area of skin (dermis) has sensory nerve fibers coming from a single spinal nerve root (see [Appendix](#)).

**Hoffman's sign/Finger Flexor reflex:** Holding the individual's middle finger loosely and flicking the fingernail downward, causing the finger to rebound slightly into extension. If the thumb flexes and adducts in response, Hoffmann's sign is present.



**Myotome:** A muscle of the back supplied by a nerve of the spine.

**Ossification of the posterior longitudinal ligament:** A ligament in the spine that travels from the neck to the sacrum. It may become thickened and cause pressure on the spinal cord and lead to nerve damage.

**Persistent debilitating pain:** Significant level of pain on a daily basis as measured as a visual analog scale score of 4 or greater and pain on a daily basis that has a documented impact on activities of daily living despite optimal conservative nonsurgical therapy as outlined in the policy and appropriate for the individual.

**Pseudarthrosis:** When bones fail to fuse with one another after spinal fusion surgery. Lack of union at the fused location.

**Smoking cessation:** Smoking cessation for at least 6 weeks prior to scheduled (non-emergent) surgery applies to smoking cigarettes, cigars, and pipe smoking of tobacco.

Laminectomy may occasionally be performed for the sole indication of radiculopathy due to herniated disc. In these cases, discectomy alone is not sufficient to relieve compression on vital structures, and laminectomy is required for adequate decompression. Compression of the spine due to herniated disc is uncommon, and there are no standardized preoperative criteria to determine which individuals may require laminectomy in addition to discectomy.

## Medical History

Documentation to establish medical necessity should include the following:

- Assessment of comorbid physical and psychological health conditions (e.g., morbid obesity, current smoking, diabetes, renal disease, osteoporosis, and severe physical deconditioning)
- History of back surgery, including minimally invasive back procedures
- Prior trial, failure, or contraindication to conservative medical/nonoperative interventions that may include but are not limited to the following:
  - Activity modification for at least 6 weeks
  - Oral analgesics and/or anti-inflammatory medications
  - Physical therapy





- Chiropractic manipulation
- Epidural steroid injections.

### **Physical Examination**

- Clinical findings including the individual's stated symptoms and duration

### **Diagnostic Testing**

- Radiologically confirmed cervical spine abnormality based on a magnetic resonance image or other neuroimaging of the cervical spine within the past 6 months
- Report of the selective nerve root injection results, if applicable to the individual's diagnostic workup

### **Benefit Application**

Prior authorization review and approval is required on all indications with submission of clinical information that supports the medical necessity for cervical spine surgery such as cervical discectomy, laminectomy, or fusion.

### **Consideration of Age**

This policy is intended for use in the adult population and is based on utilization in this population. Cervical spine surgeries are often performed when the cervical vertebrae become damaged due to injury or chronic degenerative changes. Degenerative disc changes are an age-related condition

## **Evidence Review**

---



## Description

Cervical fusion is a surgery that joins or fuses selected bones in the neck. It is performed through an incision on the front (anterior) or back (posterior) of the neck. Cervical fusion is often performed when the cervical vertebrae become damaged due to injury or chronic degenerative changes, leading to compression of the spinal cord or the cervical nerve root. The expected outcome from cervical fusion is stabilization of the vertebrae and alleviation of pain and/or weakness resulting from vertebral instability.

Bone grafts are often used, taken from elsewhere in the body or received from a bone bank. Metal implants can be used to hold the vertebrae together until new bone grows between them. Metal plates can be screwed into adjacent vertebrae to join them. An entire vertebra can be removed, and the spine then fused. A spinal disc can be removed and the adjacent vertebrae fused.

Clinical complications of cervical fusion surgery include: infection; injury to the nerves; misplaced, broken, or loosened plates, screws or implants; injury to the spinal cord; possible need for additional surgery in the future due to adjacent segment breakdown; and/or increased pain.

An adequate course of conservative treatment may avert the need for surgical intervention.

Cervical discectomy is a surgical procedure in which one or more intervertebral discs are removed. Extrusion of an intervertebral disc beyond the intervertebral space can compress the spinal nerves and result in pain, numbness, and weakness. Discectomy is intended to treat symptoms by relieving pressure on the affected nerve root(s). Discectomy can be performed by a variety of surgical approaches, with either open surgery or minimally invasive techniques.

Laminectomy is a surgical procedure in which a portion of the vertebra (the lamina) is removed to decompress the spinal cord. Removal of the lamina creates greater space for the spinal cord and the nerve roots, thus relieving compression on these structures. Laminectomy is typically performed to alleviate compression due to spinal stenosis or a space-occupying lesion.

## Background

### Disc Herniation

Extrusion of an intervertebral disc beyond the intervertebral space can compress the spinal nerves and result in symptoms of pain, numbness, and weakness.



The natural history of untreated disc herniations is not well-characterized, but most herniations will decrease in size over time due to shrinking and/or regression of the disc. Clinical symptoms will also tend to improve over time in conjunction with shrinkage or regression of the herniation.

## **Treatment**

Because most disc herniations improve over time, initial care is conservative, consisting of analgesics and a prescribed activity program tailored to individual considerations. Other potential nonsurgical interventions include opioid analgesics and chiropractic manipulation. Epidural steroid injections can also be used as a second-line intervention and are associated with short-term relief of symptoms.

However, some disc herniations will not improve over time with conservative care. A small proportion of individuals will have rapidly progressive signs and symptoms, thus putting them at risk for irreversible neurologic deficits. These individuals are considered to be surgical emergencies, and expedient surgery is intended to prevent further neurologic deterioration and allow for nerve recovery.

## **Cervical Discectomy**

The most common procedure for cervical discectomy is anterior cervical discectomy. This is an open procedure in which the cervical spine is approached through an incision in the anterior neck. Soft tissues and muscles are separated to expose the spine. The disc is removed using direct visualization. This procedure can be done with or without spinal fusion, but most commonly it is performed with fusion.

A less invasive procedure for cervical discectomy is posterior cervical discectomy and foraminotomy. This is performed through a small incision in the back of the neck. The nerves and muscles are separated using a small retractor. The spine is visualized with microscopic guidance, and a portion of the spine—the foramen—is removed to expose the spinal canal. Special instruments are used to remove a portion of the disc or the entire disc.

## **Adverse Events**

Complications of discectomy generally include bleeding, infections, and inadvertent nerve injuries. Dural puncture occurs in a small percentage of individuals, leading to leakage of



cerebrospinal fluid that can be accompanied by headaches and/or neck stiffness. In a small percentage of cases, worsening of neurologic symptoms can occur postsurgery.

## **Cervical Laminectomy**

Laminectomy is an inpatient procedure performed under general anesthesia. An incision is made in the back over the affected region, and the neck muscles are dissected to expose the spinal cord. The lamina is then removed from the vertebral body, along with any inflamed or thickened ligaments that may be contributing to compression. Following resection, the muscles are reapproximated and the soft tissues sutured back into place. The extent of laminectomy varies, but most commonly extends two levels above and below the site of maximal cord compression.<sup>1</sup>

There are numerous variations on the basic laminectomy procedure. It can be performed by minimally invasive techniques, which minimize the extent of resection. Laminoplasty is a more limited procedure in which the lamina is cut but not removed, thus allowing expansion of the spinal cord. Foraminotomy and/or foramenectomy, which involve partial or complete removal of the facet joints, may be combined with laminectomy when the spinal nerve roots are compressed at the foramen. Spinal fusion is combined with laminectomy when the instability of the spine is present preoperatively, or if the procedure is sufficiently extensive to expect postoperative spinal instability.

### **Associated Disorders**

The most common diagnosis treated with laminectomy is spinal stenosis. In spinal stenosis, the spinal canal (vertebral foramen) is narrowed, thus compressing the spinal cord. Narrowing of the spinal canal may be congenital or degenerative in origin. Other conditions that cause pressure on the spine and spinal nerve roots include those where a mass lesion is present (e.g., tumor, abscess, other localized infection).

### **Surgical Variations**

Hemilaminotomy and laminotomy, sometimes called laminoforaminotomy, are less invasive than a laminectomy. These procedures focus on the interlaminar space, where most of the pathologic changes are concentrated, minimizing resection of the stabilizing posterior spine. A laminotomy typically removes the inferior aspect of the cranial lamina, the superior aspect of the subjacent lamina, the ligamentum flavum, and the medial aspect of the facet joint. Unlike laminectomy,



laminotomy does not disrupt the facet joints, supra- and interspinous ligaments, a major portion of the lamina, or the muscular attachments. Muscular dissection and retraction are required to achieve adequate surgical visualization.

Microendoscopic decompressive laminotomy is similar to laminotomy but uses endoscopic visualization. The position of the tubular working channel is confirmed by fluoroscopic guidance, and serial dilators are used to dilate the musculature and expand the fascia. For microendoscopic decompressive laminotomy, an endoscopic curette, rongeur, and drill are used for the laminotomy, facetectomy, and foraminotomy. The working channel may be repositioned from a single incision for multilevel and bilateral dissections.

### **Adverse Events**

Complications of laminectomy can include spinal cord and nerve root injuries, which occur at rates from 0% to 10%<sup>1</sup>. Worsening myelopathy and/or radiculopathy can occur in a small percentage of individuals independent of surgical injuries. Worsening of symptoms is usually temporary, but in some cases has been permanent. Infection and bleeding can occur; hematomas following surgery often require reoperation if they are close to critical structures. Leakage of spinal fluid may occur and occasionally be persistent requiring treatment. Instability of the spine can result from extensive laminectomy involving multiple levels. This is usually an indication for spinal fusion as an adjunct to laminectomy, but if fusion is not performed, the instability may lead to progressive symptoms and additional surgery. Specific complication rates depend on the indication and location treated, surgical approach, and extent of surgery.

### **Effect of Smoking on Spinal Fusion Rates**

A systematic review of the effects of smoking on spine surgery was published by Jackson and Devine in 2016.<sup>35</sup> Four large retrospective comparative studies were included; they evaluated fusion rates in smokers and nonsmokers. The authors concluded that smoking increases the risk of nonunion in both lumbar and cervical spine procedures. A retrospective literature review by Berman et al (2017)<sup>36</sup> found that smoking significantly increases the risk of pseudarthrosis for individuals undergoing both cervical and lumbar fusion. Bishop et al (1996) prospectively studied 132 individuals requiring anterior cervical interbody fusion and found that cigarette consumption had a significant adverse effect on successful fusion rates, especially those treated with allograft bone substrate (p.0.004).<sup>37</sup>



## Summary of Evidence

Literature suggests that spinal fusion appears to provide faster relief of pain and symptoms than conservative management (i.e., physical therapy or cervical collar immobilization) in the first several months after the surgery. Over time, however, these differences diminished and clinical outcomes of cervical fusion and conservative treatment were comparable at 12 months after the intervention. Additionally, spinal fusion may cause relatively rare but significant complications. Therefore, the first line of treatment for chronic cervical pain should be a comprehensive non-operative approach. A non-emergent cervical spine fusion may be a consideration only after conservative therapy has failed and a physical examination and diagnostic imaging findings indicate neural compression at the appropriate level.

For individuals who have cervical herniated disc(s) and symptoms of radiculopathy rapidly progressing or refractory to conservative care who receive cervical discectomy, the evidence includes two randomized controlled trials (RCTs), a long-term observational study, and a systematic review. Relevant outcomes are symptoms, functional outcomes, health status measures, quality of life, and treatment-related mortality and morbidity. There is considerably less evidence on cervical discectomy than on lumbar discectomy. The best evidence on the efficacy of cervical discectomy consists of two small RCTs comparing discectomy with conservative care, and a systematic review of these trials. Although there is less evidence for this indication, it does not differ substantially from lumbar herniated disc, showing that patient-reported symptoms and disability favor surgery in the short-term, and that long-term outcomes do not differ. Because cervical discectomy closely parallels lumbar discectomy, with close similarities in anatomy and surgical procedure, it can be inferred that the benefit reported for lumbar discectomy supports a benefit for cervical discectomy. Based on the available evidence and extrapolation from studies of lumbar herniated disc, it is likely that use of discectomy for cervical herniated disc improves short-term symptoms and disability. The evidence is sufficient to determine that the technology results in an improvement in the net health outcome.

For individuals who have cervical spinal stenosis and spinal cord or nerve root compression who receive cervical laminectomy, the evidence includes systematic reviews and nonrandomized comparative studies. Relevant outcomes are symptoms, functional outcomes, health status measures, quality of life, and treatment-related mortality and morbidity. There is a lack of high-quality, comparative evidence for this indication, although what evidence there is offers outcomes similar to those for lumbar spinal stenosis. Given the parallels between cervical laminectomy and lumbar laminectomy, a chain of evidence can be developed that the benefit reported for lumbar laminectomy supports a benefit for cervical laminectomy. The evidence is sufficient to determine that the technology results in an improvement in the net health outcome.



For individuals who have space-occupying lesion(s) of the spinal canal or nerve root compression who receive cervical laminectomy, the evidence includes case series. Relevant outcomes are symptoms, functional outcomes, health status measures, quality of life, and treatment-related mortality and morbidity. Most case series are small and retrospective. They have reported that most individuals with myelopathy experience improvements in symptoms or abatement of symptom progression after laminectomy. However, this uncontrolled evidence does not provide a basis to determine the efficacy of the procedure compared with alternatives. The evidence is insufficient to determine that the technology results in an improvement in the net health outcome.

The current standard of care, clinical input obtained in 2015, clinical practice guidelines, and the absence of alternative treatments all support the use of laminectomy for space-occupying lesions of the spinal canal. As a result, laminectomy may be considered medically necessary for individuals with space-occupying lesions of the spinal cord.

### Ongoing and Unpublished Clinical Trials

A currently unpublished trial that might influence this review is listed in [Table 1](#).

**Table 1. Summary of Key Trials**

NCT No.	Trial Name	Planned Enrollment	Completion Date
<b>Unpublished</b>			
<a href="#">NCT02215551</a>	Toward Optimizing Decompressive Laminectomy Outcomes: Looking Outside the Spine	239	Jan 2023

NCT: national clinical trial

### Clinical Input Received From Physician Specialty Societies and Academic Medical Centers

While the various physician specialty societies and academic medical centers may collaborate with and make recommendations during this process, through the provision of appropriate



reviewers, input received does not represent an endorsement or position statement by the physician specialty societies or academic medical centers, unless otherwise noted.

In response to requests, input was received from two specialty societies and four academic medical centers when this policy was in development in 2015. Input informed criteria for medical necessity for the indications of mass lesions and cervical laminectomy.

## Practice Guidelines and Position Statements

The purpose of the following information is to provide reference material. Inclusion does not imply endorsement or alignment with the policy conclusions.

Guidelines or position statements will be considered for inclusion if they were issued by, or jointly by, a US professional society, an international society with US representation, or National Institute for Health and Care Excellence (NICE). Priority will be given to guidelines that are informed by a systematic review, include strength of evidence ratings, and include a description of management of conflict of interest.

## North American Spine Society

In 2011, the North American Spine Society (NASS) published evidence-based clinical guidelines on the diagnosis and treatment of cervical radiculopathy from degenerative disorders.<sup>28</sup> The guidelines included evaluations of anterior cervical discectomy (ACD), ACD with fusion, ACD with instrumented fusion, ACD with fusion plus a plate, and posterior laminoforaminotomy. Recommendations are listed in [Table 2](#).

**Table 2. Recommendations Treating Cervical Radiculopathy From Degenerative Disorders**

Recommendations	GOR <sup>a</sup>
Surgical intervention is suggested for the rapid relief of symptoms when compared to medical/interventional treatment.	B
Surgery is an option to produce and maintain favorable long-term (>4 years) outcomes.	C
Both ACD and ACDF are suggested as comparable treatment strategies, producing similar clinical outcomes.	B





Recommendations	GOR <sup>a</sup>
ACDF and total disc arthroplasty are suggested as comparable treatments, resulting in similarly successful short-term outcomes.	B
Both ACDF with and without a plate are suggested as comparable treatments, resulting in similar clinical outcomes and fusion rates.	B
Either ACDF or PLF are suggested for treatment of single level degenerative cervical radiculopathy secondary to foraminal soft disc herniation to achieve comparably successful clinical outcomes.	B

ACD: anterior cervical discectomy; ACDF: anterior cervical discectomy with fusion; GOR: grade of recommendation; PLF: posterior laminoforaminotomy.

<sup>a</sup> Grade B: fair evidence (level II or III studies with consistent findings); grade C: poor quality evidence (level IV or V studies).

## Institute for Clinical and Economic Review (ICER) Evaluation – 2013

In 2013, Washington State Health Care Authority commissioned the ICER to evaluate the comparative clinical effectiveness and comparative value of spinal fusion and its alternatives in patients with cervical degenerative disc disease (DDD).<sup>29</sup>

The focus of this appraisal was on adults (>17 years of age) with cervical DDD symptoms, including neck pain, arm pain, and/or radiculopathic symptoms (e.g., numbness, tingling); these symptoms could occur with or without the presence of spondylosis. In all cases, the target population was focused on patients whose symptoms have persisted despite an initial short course (i.e., 4-6 weeks) of self-care and conservative management.

Evidence was sought to answer several key questions, including:

### **What is the comparative clinical effectiveness of cervical fusion for DDD relative to that of conservative management approaches, minimally-invasive procedures, and other forms of surgery?**

ICER conferred a “Comparable” rating for spinal fusion vs. conservative management for radiculopathic symptoms. They stated: “For patients with clinical symptoms of radiculopathy and radiographic evidence of nerve root compression there is not a large evidence base comparing outcomes between spinal fusion and conservative management. We identified only 1 RCT and 1 comparative cohort study, neither of which stood out for their methodologic rigor, size, or generalizability. Despite variability in study design, entry criteria, and outcomes measured, findings were reasonably consistent. Specifically, spinal fusion appeared to provide faster relief of pain and symptoms than conservative management (i.e., physical therapy or cervical collar immobilization) in the short term. Over time, however, these differences diminished and no material differences in outcome were observed by 12 months after intervention. ICER cited a Cochrane review by Nikolaidis and colleagues to determine whether surgical treatment of



cervical radiculopathy or myelopathy was associated with improved outcome compared with conservative management. Two trials (N = 149) were included. In both trials, allocation concealment was inadequate and arrangements for blinding of outcome assessment were unclear. One trial (81 patients with cervical radiculopathy) found that surgical decompression was superior to physiotherapy or cervical collar immobilization in the short-term for pain, weakness or sensory loss; at one year, there were no significant differences between groups. One trial (68 patients with mild functional deficit associated with cervical myelopathy) found no significant differences between surgery and conservative treatment in three years following treatment. A substantial proportion of cases were lost to follow-up. The authors concluded that it was unclear whether the short-term risks of surgery are offset by long-term benefits. There was low quality evidence that surgery may provide pain relief faster than physiotherapy or hard collar immobilization in patients with cervical radiculopathy; but there is little or no difference in the long-term. There was very low quality evidence that patients with mild myelopathy felt subjectively better shortly after surgery, but there was little or no difference in the long-term.

Because of this, and because spinal fusion may cause relatively rare but significant complications, we deemed the overall comparative clinical effectiveness of fusion to conservative management “Comparable”. In some patients, however, neck pain and related symptoms may be so severe and disabling that the faster relief potentially afforded by fusion surgery would also allow a quicker return to work and other normal activities. For such patients, fusion might in fact be considered “Incremental” in comparison to ongoing conservative management.

Another key question concerned potential harms associated with cervical fusion compared to conservative management:

**What are the adverse events and other potential harms associated with cervical fusion compared to conservative management approaches, minimally-invasive procedures, and other forms of surgery?**

In analyzing data from randomized controlled trials (RCTs) and comparative cohorts, ICER found that the rate of harm and complications from cervical fusion were significantly greater than those from conservative treatment. Some of the highest rates of potential harm from fusion were events of infection (0-13%), adjacent segment disease (7-16%), paresthesia (14%), dysphagia (3-17%), pseudoarthrosis (8%), and neurological decline (3-23%). Conservative treatment harms were relatively minor, with the exception of neurological decline (14.2%) and paresthesia (8%).

In summary, literature suggests that spinal fusion appeared to provide faster relief of pain and symptoms than conservative management (i.e., physical therapy or cervical collar



immobilization) in the first several months after the surgery. Over time, however, these differences diminished and clinical outcomes of cervical fusion and conservative treatment were comparable at 12 months after the intervention. Additionally, spinal fusion may cause relatively rare but significant complications. Therefore, the first line of treatment for chronic cervical pain should be a comprehensive non-operative approach. A non-emergent cervical spine fusion may be a consideration only after conservative therapy has failed and a physical examination and diagnostic imaging findings indicate neural compression at the appropriate level.

## Medicare National Coverage

There is no national coverage determination.

## Regulatory Status

Discectomy, laminectomy and fusion are surgical procedures and, as such, are not subject to regulation by the US Food and Drug Administration. Some instrumentation used during discectomy, laminectomy or fusion may be subject to Food and Drug Administration approval.

## References

1. Epstein NE. Laminectomy for cervical myelopathy. *Spinal Cord*. Jun 2003;41(6):317-327. PMID 12746738.
2. Kadanka Z, Mares M, Bednanik J, et al. Approaches to spondylotic cervical myelopathy: conservative versus surgical results in a 3-year follow-up study. *Spine (Phila Pa 1976)*. Oct 15 2002;27(20):2205-2210; discussion 2210-2201. PMID 12394893.
3. Fehlings MG, Wilson JR, Kopjar B, et al. Efficacy and safety of surgical decompression in patients with cervical spondylotic myelopathy: results of the AOSpine North America prospective multi-center study. *J Bone Joint Surg Am*. Sep 18 2013;95(18):1651-1658. PMID 24048552.
4. Huang M, Gao X, Cheng J, et al. Laminoplasty versus laminectomy and fusion for multilevel cervical compressive myelopathy: A meta-analysis. *Medicine (Baltimore)*. Jun 2016; 95(23): e03588. PMID 27281067.
5. Phan K, Scherman DB, Xu J, et al. Laminectomy and fusion vs laminoplasty for multi-level cervical myelopathy: a systematic review and meta-analysis. *Eur Spine J*. Jan 2017;26(1):94-103. PMID 27342611.
6. Singhatanadgige W, Limthongkul W, Valone F, 3rd, et al. Outcomes following laminoplasty or laminectomy and fusion in patients with myelopathy caused by ossification of the posterior longitudinal ligament: a systematic review. *Global Spine J*. Nov 2016;6(7):702-709. PMID 27781191.



7. Ghogawala Z, Terrin N, Dunbar MR, et al. Effect of Ventral vs Dorsal Spinal Surgery on Patient-Reported Physical Functioning in Patients With Cervical Spondylotic Myelopathy: A Randomized Clinical Trial. *JAMA*. Mar 09 2021; 325(10): 942-951. PMID 33687463.
8. Yoshii T, Tomizawa S, Hirai T, et al. Surgical Outcomes in Selective Laminectomy and Conventional Double-Door Laminoplasty for Cervical Spondylotic Myelopathy. *Orthopedics*. Jul 01 2020; 43(4): e311-e315. PMID 32501516.
9. Kotter MRN, Tetreault L, Badhiwala JH, et al. Surgical Outcomes Following Laminectomy With Fusion Versus Laminectomy Alone in Patients With Degenerative Cervical Myelopathy. *Spine (Phila Pa 1976)*. Dec 15 2020; 45(24): 1696-1703. PMID 32890295.
10. Zong S, Zeng G, Xiong C, et al. Treatment results in the differential surgery of intradural extramedullary schwannoma of 110 cases. *PLoS One*. 2013; 8(5): e63867. PMID 23724010.
11. Tredway TL, Santiago P, Hrubes MR, et al. Minimally invasive resection of intradural-extramedullary spinal neoplasms. *Neurosurgery*. Feb 2006; 58(1 Suppl): ONS52-8; discussion ONS52-8. PMID 16479629.
12. Sattari SA, Ghanavatian M, Feghali J, et al. Anterior cervical discectomy and fusion versus posterior decompression in patients with degenerative cervical myelopathy: a systematic review and meta-analysis. *J Neurosurg Spine*. Feb 24 2023: 1-13. PMID 36840737.
13. Nakashima H, Tetreault L, Nagoshi N, et al. Comparison of Outcomes of Surgical Treatment for Ossification of the Posterior Longitudinal Ligament Versus Other Forms of Degenerative Cervical Myelopathy: Results from the Prospective, Multicenter AOSpine CSM-International Study of 479 Patients. *J Bone Joint Surg Am*. Mar 02 2016; 98(5): 370-8. PMID 26935459.
14. Kommu R, Sahu BP, Purohit AK. Surgical outcome in patients with cervical ossified posterior longitudinal ligament: A single institutional experience. *Asian J Neurosurg*. Oct-Dec 2014; 9(4): 196-202. PMID 25685216.
15. Lee CH, Jahng TA, Hyun SJ, et al. Expansive Laminoplasty Versus Laminectomy Alone Versus Laminectomy and Fusion for Cervical Ossification of the Posterior Longitudinal Ligament: Is There a Difference in the Clinical Outcome and Sagittal Alignment?. *Clin Spine Surg*. Feb 2016; 29(1): E9-15. PMID 25075990.
16. Yu H, Li X, Chen S, et al. Comparative Effectiveness and Safety of Anterior Cervical Corpectomy with Fusion, Laminoplasty, and Laminectomy and Instrumented Fusion for Ossification of the Posterior Longitudinal Ligament: A Systematic Review and Network Meta-Analysis. *J Invest Surg*. Jan 20 2021: 1-10. PMID 33472478.
17. Cao B, Chen J, Yuan B, et al. Comparison of the outcome after anterior cervical ossified posterior longitudinal ligament en bloc resection versus posterior total laminectomy and fusion in patients with ossification of the cervical posterior longitudinal ligament: a prospective randomized controlled trial. *Bone Joint J*. Mar 15 2023; 105-B(4): 412-421. PMID 36924177.
18. Mo K, Gupta A, Laljani R, et al. Laminectomy Versus Laminectomy with Fusion for Intradural Extramedullary Tumors: A Systematic Review and Meta-Analysis. *World Neurosurg*. Aug 2022; 164: 203-215. PMID 35487493.
19. Byvaltsev V, Polkin R, Kalinin A, et al. Laminoplasty versus Laminectomy in the Treatment of Primary Spinal Cord Tumors in Adult Patients: A Systematic Review and Meta-analysis of Observational Studies. *Asian Spine J*. Jun 2023; 17(3): 595-609. PMID 36717092
20. Piccolo R, Passanisi M, Chiaramonte I, et al. Cervical spinal epidural abscesses. A report on five cases. *J Neurosurg Sci*. Mar 1999; 43(1): 63-7. PMID 10494668
21. Persson LC, Moritz U, Brandt L, et al. Cervical radiculopathy: pain, muscle weakness and sensory loss in patients with cervical radiculopathy treated with surgery, physiotherapy or cervical collar. A prospective, controlled study. *Eur Spine J*. Jan 1997;6(4):256-266. PMID 9294750.
22. Peolsson A, Soderlund A, Engquist M, et al. Physical function outcome in cervical radiculopathy patients after physiotherapy alone compared with anterior surgery followed by physiotherapy: a prospective randomized study with a 2-year follow-up. *Spine (Phila Pa 1976)*. Feb 15 2013;38(4):300-307. PMID 23407407.
23. Faught RW, Church EW, Halpern CH, et al. Long-term quality of life after posterior cervical foraminotomy for radiculopathy. *Clin Neurol Neurosurg*. Mar 2016;142:22-25. PMID 26802616.

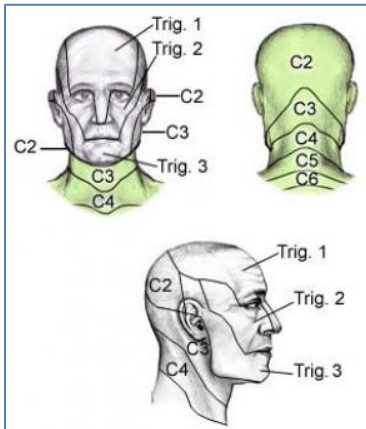


24. Jacobs WCH, Anderson PG, van Limbeek J, et al. Single or double-level anterior interbody fusion techniques for cervical degenerative disc disease. *Cochrane Database of Syst Rev.* 2004;(4):CD004958.
25. Fouyas IP, Statham PFX, Sandercock PAG, Lynch C. Surgery for cervical radiculomyelopathy. *Cochrane Database of Syst Rev.* 2001;(3):CD001466.
26. Ryken TC, Heary RF, Matz PG, et al; Joint Section on Disorders of the Spine and Peripheral Nerves of the American Association of Neurological Surgeons and Congress of Neurological Surgeons. Cervical laminectomy for the treatment of cervical degenerative myelopathy. *J Neurosurg Spine.* 2009;11(2):142-149.
27. Matz PG, Holly LT, Groff MW, et al. Indications for anterior cervical decompression for the treatment of cervical degenerative radiculopathy. *J Neurosurg: Spine.* August 2009; 11(2): 174-182. PMID 19769497.
28. Bono CM, Ghiselli G, Gilbert TJ, et al. An evidence-based clinical guideline for the diagnosis and treatment of cervical radiculopathy from degenerative disorders. *Spine J* Jan,2011; 11(1): 64-72. PMID 21168100.
29. Washington State Health Care Authority. Health Technology Assessment. Cervical Spinal Fusion for degenerative Disc Disease. February 21, 2013. [http://hca.wa.gov/assets/program/022113\\_csf\\_final\\_report\[1\].pdf](http://hca.wa.gov/assets/program/022113_csf_final_report[1].pdf) Accessed July 8, 2024.
30. Murphy DR, Hurwitz EL, Gregory A, et al. A nonsurgical approach to the management of patients with cervical radiculopathy: a prospective observational cohort study. *J Manipulative Physiol Ther.* 2006 May;29(4):279-87. PMID 16690382.
31. Nikolaidis I, Fouyas IP, Sandercock PA, et al. Surgery for cervical radiculopathy or myelopathy. *Cochrane Database Syst Rev.* 2010 Jan 20;(1):CD001466. doi: 10.1002/14651858.CD001466.pub3.
32. Bydon M, Xu R, Macki M, et al. Adjacent segment disease after anterior cervical discectomy and fusion in a large series. *Neurosurgery.* 2014; 74(2):139-146.
33. Wu AM, Xu H, Mullinix KP, et al. Minimum 4-year outcomes of cervical total disc arthroplasty versus fusion: a meta-analysis based on prospective randomized controlled trials. *Medicine (Baltimore).* 2015 Apr;94(15):e665. PMID 25881841.
34. Kishner S, et al. Dermatomes Anatomy. Medscape reference, 2015. Web. Available at URL address: <http://emedicine.medscape.com/article/1878388-overview#a2>. Accessed July 8, 2024.
35. Jackson KL, 2nd, Devine JG. The effects of smoking and smoking cessation on spine surgery: a systematic review of the literature. *Global Spine J.* Nov 2016;6(7):695-701. PMID 27781190.
36. Berman D, Oren JH, Bendo J, et al. The effect of smoking on spinal fusion. *Int J Spine Surg* 2017; 11:29. Doi: 10.14444/4029. PMID: 29372133.
37. Bishop RC, Moore KA, Hadley MN. Anterior cervical interbody fusion using autogenic and allogeneic bone graft substrate: a prospective comparative analysis. *J Neurosurg* 1996;85 (2):206-10. PMID:8755747.
38. Alonso F, Rustagi T, Schmidt C, et al. Failure Patterns in Standalone Anterior Cervical Discectomy and Fusion Implants. *World Neurosurg.* 2017 Dec; 108:676-682. PMID 28942019.
39. Park S, Lee DH, Ha JK, et al. How does screw migration or fracture after anterior cervical plate fixation affect the radiographic and clinical outcomes? *Clin Spine Surg.* 2019 Nov 1; 32(9):398-402. PMID 31162182.

## Appendix



Image 1



Appendix Table 1. Dermatomes of the Head and Neck

Spinal Component	Skin Distribution
Divisions of the trigeminal nerve (cranial nerve [CN] V1, V2, and V3)	Most of the skin of the face, including anterior aspect of lower jaw (CN V3); the area of skin in front of both ears; superior part of the lateral aspect of the auricle (CN V3)
Cervical plexus (ventral rami of C2-C4)	Skin over the angle of the mandible, anterior to and behind the ear, the anterior neck and back of the head and neck; inferior part of the lateral aspect of the auricle and skin on medial aspect of the auricle; the lateral and anterior aspects of the neck
Greater occipital nerve (dorsal ramus of C2), third occipital nerve (dorsal ramus of C3), and the posterior divisions of C4-C6	The posterior aspect of the head (C2) and neck (C3) with C4-C6 innervating the back of the neck

Image 2

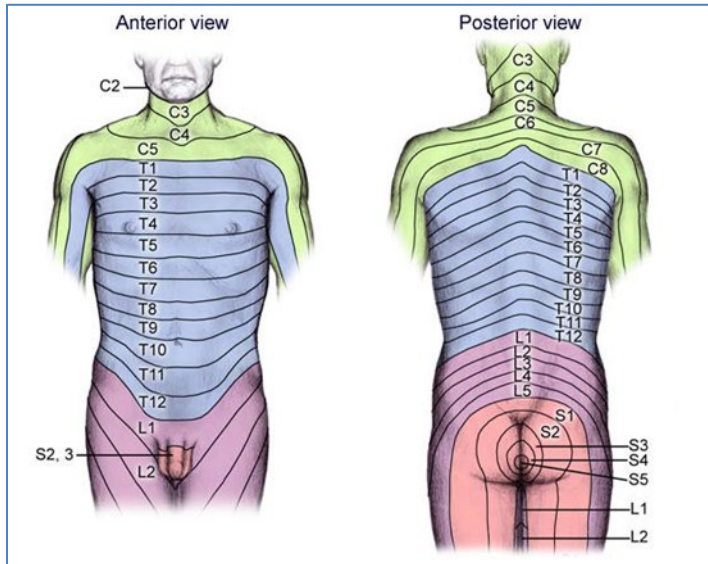
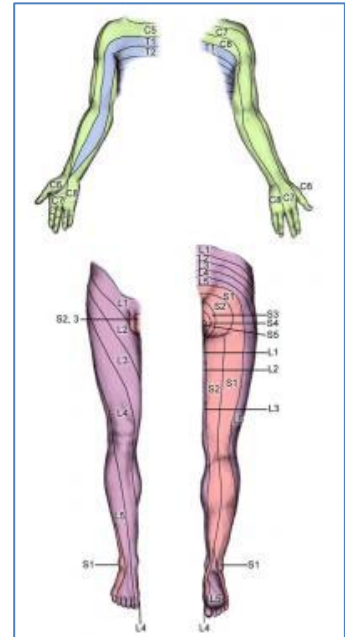


Image 3



Appendix Table 2. Dermatomes of the Upper Extremity

Spinal Component	Skin Distribution
Third and fourth cervical nerves	Limited area of skin over the root of the neck, upper aspect of the pectoral region, and shoulder
C5 dermatome	Lateral aspect of the upper extremities at and above the elbow
C6 dermatome	The forearm and the radial side of the hand
C7 dermatome	The middle finger
C8 dermatome	The skin over the small finger and the medial aspect of each hand
T1 dermatome	The medial side of the forearm
T2 dermatome	The medial and upper aspect of the arm and the axillary region

## History

Date	Comments
9/08/14	New Policy. Added to UM section. May be considered medically necessary when criteria are met. Policy approved with a hold for provider notification and will be effective December 15, 2014.
11/04/14	Minor update. Policy title updated; order change in words only for improved clarification.
12/22/14	Interim Review. Policy renumbered; moved from UM section (11.01.505) to Surgery section (7.01.560). Reference #4 removed.
02/10/15	Interim Review. All information specific to posterior cervical removed from policy statement. Title revised to note that criteria apply to anterior cervical decompression and fusion only and to adults only. Definition of corpectomy in Policy Guidelines deleted and definition of cervical radiculopathy expanded. Codes for posterior (22600/22614) deleted.
05/12/15	Minor update. "With or Without Fusion" removed from title for purposes of clarification. Additional clarifications: the word "cervical" added to multi-level fusion statement and note added that decompression as a stand-alone procedure is not subject to medical review.
09/08/15	Annual Review. Abbreviation "OPLL" added to policy statement for ossification of posterior longitudinal ligament. Dermatome graphics added to Appendix. Rationale updated and reference added. Policy statement revised as noted.
11/10/15	Interim Review. Added Documentation section to Policy Guidelines stating medical necessity is established by submitting documentation of medical history, physical findings, and diagnostic imaging results that demonstrate need for cervical spine surgery. (No documentation guidance was in the policy previously). Policy statements unchanged.
05/01/16	Annual Review, approved April 12, 2016. Policy statement revised: Timeframe for completion of diagnostic imaging changed from 6 months to 12 months, consistent with documentation requirements in Policy Guidelines. Rationale updated and reference added.
05/24/16	Update Related Policies. Removed 7.01.146 as it was added in error. Replaced with 7.01.551.
11/01/16	Interim review, approved October 11, 2016. Clarified cervical radiculopathy statement to show that imaging needs to show spinal stenosis and nerve root compression, and added herniated disk and osteophytes to physical findings. Clarified spondylotic myelopathy policy statement that imaging needs to show spinal cord compression and added ossification of posterior longitudinal ligament to list of physical findings. Policy moved into new format.
01/01/17	Interim Review, approved December 13, 2016. Policy statement revised: Requests for fusions of more than 2 levels must be reviewed by a medical director.





Date	Comments
10/01/17	Annual Review, approved September 5, 2017. No changes to policy statement, no new references.
03/01/18	Note added that this policy has been revised. Added link to revised policy that will become effective June 1, 2018.
04/15/18	Minor update, removed 11.01.524 from Related Policies as Anterior Cervical Spine Decompression and Fusion in Adults was removed from the Site of Service program. Removed link to revised policy.
06/08/18	Minor edit. Policy criteria bullets changed from "spinal stenosis <u>and</u> nerve root compression" to "spinal stenosis <u>or</u> nerve root compression".
09/21/18	Minor update. Added Consideration of Age statement.
11/01/18	Annual Review, approved October 9, 2018, effective February 1, 2019. Literature review through September 2018. References 10-15 added. Title changed from "Anterior Cervical Spine Decompression and Fusion in Adults" to "Cervical Spine Surgeries: Discectomy, Laminectomy, and Fusion in Adults". Policy statements added for posterior cervical fusion, cervical discectomy, and cervical laminectomy. Chiropractic care added as a nonoperative therapy. Added codes 22600, 63020 & 63045.
10/01/19	Annual Review, approved September 10, 2019. Policy updated with literature review through April 2019, references 16-30 added. Policy statement revised for signs and symptoms of cervical myelopathy or cord compression for greater clarity. Otherwise policy statements unchanged.
04/01/20	Delete policy, approved March 10, 2020. This policy will be deleted effective July 2, 2020, and replaced with InterQual criteria for dates of service on or after July 2, 2020.
06/10/20	Interim Review, approved June 9, 2020, effective June 10, 2020. This policy is reinstated immediately and will no longer be deleted or replaced with InterQual criteria on July 2, 2020.
09/01/20	Annual Review, approved August 4, 2020. Policy updated with literature review through April 2020; no references added. Policy statements unchanged.
10/01/20	Coding update. Added CPT code 22614.
12/01/20	Interim Review, approved November 19, 2020. Edits made to conservative care policy statements for greater clarity and consistency.
09/01/21	Annual Review, approved August 3, 2021. Policy updated with literature review through April 26, 2021; references added. Policy statements unchanged.
10/01/21	Interim Review, approved September 14, 2021. Review for site of service added to single-level cervical decompression and single level cervical fusion procedures after 90-day provider notification. Site of service review added to CPT codes 22551, 22554, 22600, 63020 and 63045. This addition is effective for dates of service January 7, 2022 and after.
01/01/22	Coding update, updated coding description of CPT codes 22600 & 22614.



Date	Comments
06/01/22	Interim Review, approved May 10, 2022. Added spine fracture/dislocation and revision surgery for implant/instrumentation failure to medically necessary criteria. Modified criteria for pseudoarthrosis. Changes become effective for dates of service on or after September 2, 2022. References added.
09/01/22	Annual Review, approved August 22, 2022. Policy updated with literature review through April 16, 2022; no references added. Minor editorial refinements to Ppolicy statements; intent unchanged except for minor edits only.
09/01/23	Annual Review, approved August 21, 2023. Changed the wording from "patient" to "individual" throughout the policy for standardization. Policy updated with literature review through May 5, 2023; references added. Minor editorial refinements to policy statements; intent unchanged.
07/01/24	Coding update. Added CPT code 63048.
09/01/24	Annual Review, approved August 12, 2024. Policy updated with literature review through May 8, 2024; no references added, however, references were reorganized. Policy statements unchanged. The following policy changes are effective December 5, 2024, following 90-day provider notification. Added CPT codes 63001, 63015, 63040, 63043, 63050, 63051, 63075, 63076, 63081 and 63265.

**Disclaimer:** This medical policy is a guide in evaluating the medical necessity of a particular service or treatment. The Company adopts policies after careful review of published peer-reviewed scientific literature, national guidelines and local standards of practice. Since medical technology is constantly changing, the Company reserves the right to review and update policies as appropriate. Member contracts differ in their benefits. Always consult the member benefit booklet or contact a member service representative to determine coverage for a specific medical service or supply. CPT codes, descriptions and materials are copyrighted by the American Medical Association (AMA). ©2024 Premera All Rights Reserved.

**Scope:** Medical policies are systematically developed guidelines that serve as a resource for Company staff when determining coverage for specific medical procedures, drugs or devices. Coverage for medical services is subject to the limits and conditions of the member benefit plan. Members and their providers should consult the member benefit booklet or contact a customer service representative to determine whether there are any benefit limitations applicable to this service or supply. This medical policy does not apply to Medicare Advantage.

