

## MEDICAL POLICY – 7.01.605

# Shoulder Open Procedures


Effective Date: **Sep. 4, 2026\***  
Last Revised: May 12, 2026  
Replaces: N/A

RELATED MEDICAL POLICIES:  
7.01.590 Shoulder Arthroplasty in Adults

\*View current policy version here

Select a hyperlink below to be directed to that section.

[POLICY CRITERIA](#) | [DOCUMENTATION REQUIREMENTS](#) | [CODING](#)  
[RELATED INFORMATION](#) | [EVIDENCE REVIEW](#) | [REFERENCES](#) | [HISTORY](#)

 Clicking this icon returns you to the hyperlinks menu above.

## Introduction

Shoulder arthrotomy is a type of surgery where a surgeon makes an open incision into the shoulder joint to diagnose or treat a problem. This procedure is usually done when other, less invasive methods like imaging tests or arthroscopy (using a small camera) aren't enough. During the surgery, the surgeon can look directly at the bones, cartilage, muscles, and other tissues in the shoulder. They may remove infected tissue, repair damage, or drain fluid from the joint. It is often used to treat serious infections, injuries, or certain joint diseases. Because it is an "open" surgery (not done through small incisions), recovery may take longer, and individuals may need physical therapy to regain strength and movement in the shoulder. The goal is to relieve pain, treat the underlying problem, and help the shoulder function better. This policy describes when open shoulder arthrotomy procedures may be considered medically necessary.

**Note:** The Introduction section is for your general knowledge and is not to be taken as policy coverage criteria. The rest of the policy uses specific words and concepts familiar to medical professionals. It is intended for providers. A provider can be a person, such as a doctor, nurse, psychologist, or dentist. A provider also can be a place where medical care is given, like a hospital, clinic, or lab. This policy informs them about when a service may be covered.

## Policy Coverage Criteria

**Hyperlinks to criteria:**

[Acromioclavicular \(AC\) separation](#)

[Decompression of subacromial space or acromioplasty for rotator cuff tendonitis](#)

[Full thickness rotator cuff repair](#)

[Resection of distal clavicle](#)

[Shoulder dislocation](#)

[Synovectomy \(major or complete\)](#)

[All other indications or situations](#)

Indication	Medical Necessity
<b>Acromioclavicular (AC) separation (CPT 23550, 23552)</b>	<p><b>Shoulder arthroscopy for acromioclavicular (AC) separation may be considered medically necessary when ALL the following criteria are met:</b></p> <ul style="list-style-type: none"><li>• One or more of is present:<ul style="list-style-type: none"><li>○ Recent traumatic event</li><li>○ Shoulder pain</li><li>○ Deformity</li></ul></li></ul> <p><b>AND</b></p> <ul style="list-style-type: none"><li>• Rockwood type III or higher rated injury (see <a href="#">Related Information</a>) diagnosed by imaging*</li></ul> <p>* Imaging gold standard is X-ray; MRI may be used for soft tissue assessment or if X-ray is inconclusive; ultrasound is not typically used for grading AC separation.</p>
<b>Decompression of subacromial space or acromioplasty for rotator cuff tendonitis (CPT 23130)</b>	<p><b>Shoulder arthroscopy for decompression of subacromial space or acromioplasty for rotator cuff tendonitis may be considered medically necessary when ALL the following criteria are met:</b></p> <ul style="list-style-type: none"><li>• History of disabling shoulder pain with loss of shoulder function which interferes with activities of daily living (ADLs)</li></ul> <p><b>AND</b></p> <ul style="list-style-type: none"><li>• At least one of the following positive orthopedic tests on physical exam compared to the non-affected shoulder<ul style="list-style-type: none"><li>○ Hawkins-Kennedy Impingement Test</li></ul></li></ul>



Indication	Medical Necessity
	<ul style="list-style-type: none"> <li>○ Neer Impingement Test</li> </ul> <p><b>AND</b></p> <ul style="list-style-type: none"> <li>• Documentation of three months of failed non-operative, conservative management as demonstrated by a trial of one or more of the following medications: <ul style="list-style-type: none"> <li>○ Non-steroidal anti-inflammatories (NSAIDs)</li> <li>○ Acetaminophen</li> <li>○ Subacromial corticosteroid injection, as appropriate</li> </ul> </li> </ul> <p><b>AND</b></p> <ul style="list-style-type: none"> <li>• A trial of the following physical measures: <ul style="list-style-type: none"> <li>○ Physical therapy (PT) and/or directed home exercise for at least 6 weeks</li> </ul> </li> </ul> <p><b>AND</b></p> <ul style="list-style-type: none"> <li>• Plain x-rays or imaging (MRI or CT) demonstrate findings consistent with subacromial impingement, (e.g., Type II or III acromions*)</li> </ul> <p>* Type II acromion is curved and Type III acromion is hooked; this describes the shape of the acromion bone. These shapes can reduce the space of the rotator cuff tendons and bursa and lead to subacromial impingement.</p>
<p><b>Full thickness rotator cuff repair (CPT 23410, 23412, 23420)</b></p>	<p><b>Shoulder arthroscopy for full thickness rotator cuff repair may be considered medically necessary when ALL the following criteria are met:</b></p> <ul style="list-style-type: none"> <li>• History of disabling shoulder or upper arm pain with loss of shoulder function which interferes with ADLs</li> </ul> <p><b>AND</b></p> <ul style="list-style-type: none"> <li>• Shoulder pain or weakness on resisted abduction or rotation</li> </ul> <p><b>AND</b></p> <p>One of the following positive orthopedic tests is present:</p> <ul style="list-style-type: none"> <li>○ Drop arm test</li> <li>○ Painful arc test</li> <li>○ Empty can test (aka Jobe test)</li> <li>○ Weakness of external rotation (lag/dropping sign)</li> </ul> <p><b>AND</b></p> <ul style="list-style-type: none"> <li>• Imaging demonstrates partial or full-thickness rotator cuff tear (may be associated with muscle atrophy, fatty replacement, or</li> </ul>



Indication	Medical Necessity
	<p>tendon retraction, if tear is chronic) (See <a href="#">Related Information</a> for Ellman and Cofield grade classifications)</p> <p><b>AND</b></p> <ul style="list-style-type: none"> <li>• Documentation of three months of failed non-operative, conservative management* as demonstrated by a trial of one or more of the following medications: <ul style="list-style-type: none"> <li>○ NSAIDs</li> <li>○ Acetaminophen</li> <li>○ Subacromial corticosteroid injection, as appropriate</li> </ul> </li> </ul> <p><b>AND</b></p> <ul style="list-style-type: none"> <li>• A trial of the following physical measures: <ul style="list-style-type: none"> <li>○ PT and/or directed home exercise for at least 6 weeks</li> </ul> </li> </ul> <p>* Conservative management is not required in an acute traumatic injury with a complete tear with debilitating pain and loss of function</p>
<p><b>Resection of distal clavicle (CPT 23120)</b></p> <ul style="list-style-type: none"> <li>• AC joint arthritis</li> </ul>	<p><b>Shoulder arthrotomy for resection of distal clavicle for AC joint arthritis may be considered medically necessary when ALL the following criteria are met:</b></p> <ul style="list-style-type: none"> <li>• History of disabling shoulder pain with loss of shoulder function which interferes with ADLs</li> </ul> <p><b>AND</b></p> <ul style="list-style-type: none"> <li>• Localized tenderness to palpation of the AC joint</li> </ul> <p><b>AND</b></p> <ul style="list-style-type: none"> <li>• At least one of the following positive orthopedic tests (see <a href="#">Related Information</a>) on physical exam compared to the non-affected shoulder <ul style="list-style-type: none"> <li>○ Cross-Body Adduction Test (aka Scarf Test, Cross-Over Adduction Test)</li> <li>○ Resisted AC Joint Extension Test</li> </ul> </li> </ul> <p><b>AND</b></p> <ul style="list-style-type: none"> <li>• Documentation of three months of failed non-operative, conservative management as demonstrated by a trial of one or more of the following medications: <ul style="list-style-type: none"> <li>○ NSAIDs</li> <li>○ Acetaminophen</li> <li>○ AC joint corticosteroid injection, as appropriate</li> </ul> </li> </ul>



Indication	Medical Necessity
	<p><b>AND</b></p> <ul style="list-style-type: none"> <li>• A trial of the following physical measures: <ul style="list-style-type: none"> <li>○ PT and/or directed home exercise for at least 6 weeks</li> </ul> </li> </ul> <p><b>AND</b></p> <ul style="list-style-type: none"> <li>• Plain x-rays or imaging (MRI or CT) demonstrate findings consistent with AC joint arthritis</li> </ul>
<p><b>Shoulder dislocation (CPT 23450, 23455, 23460, 23462, 23465, 23466, 23660, 23670, 23680)</b></p>	<p><b>Shoulder arthroscopy with or without capsulorrhaphy for initial shoulder dislocation may be considered medically necessary when ALL the following criteria are met:</b></p> <ul style="list-style-type: none"> <li>• History of shoulder dislocation or subluxation with disabling shoulder pain and loss of shoulder function which interferes with ADLs</li> </ul> <p><b>AND</b></p> <ul style="list-style-type: none"> <li>• Instability found on physical examination demonstrated by any of the following positive orthopedic tests/signs (see <a href="#">Related Information</a>): <ul style="list-style-type: none"> <li>○ Anterior or posterior apprehension test</li> <li>○ Load and shift test</li> <li>○ Sulcus sign</li> </ul> </li> </ul> <p><b>AND</b></p> <ul style="list-style-type: none"> <li>• MRI findings demonstrate at least one of the following <ul style="list-style-type: none"> <li>○ A labral lesion consistent with clinical instability (e.g., Bankart lesion)</li> <li>○ Hill-Sachs lesion</li> <li>○ Capsular tear (thickening and edema of the joint)</li> <li>○ Capsular redundancy with clinical multidirectional instability (shoulder joint capsule is loose or stretched)</li> </ul> </li> </ul> <p><b>AND</b></p> <ul style="list-style-type: none"> <li>• Documentation of three months of failed non-operative, conservative management* as demonstrated by a trial of one or more of the following medications: <ul style="list-style-type: none"> <li>○ NSAIDs</li> <li>○ Acetaminophen</li> <li>○ Intra-articular corticosteroid injection</li> </ul> </li> </ul>



Indication	Medical Necessity
	<p><b>AND</b></p> <ul style="list-style-type: none"> <li>• A trial of the following physical measures: <ul style="list-style-type: none"> <li>○ PT and/or directed home exercise for at PT for at least 6 weeks</li> </ul> </li> </ul> <p>* Conservative management is not required in an acute traumatic injury when EITHER of the following conditions is present:</p> <ul style="list-style-type: none"> <li>• Irreducible shoulder dislocation, or</li> <li>• Anterior shoulder instability in competitive contact or collision athletes</li> </ul>
<p><b>Synovectomy (CPT 23105, 23106)</b></p> <ul style="list-style-type: none"> <li>• Major</li> <li>• Complete</li> </ul>	<p><b>Shoulder arthrotomy for synovectomy (major or complete) (may be considered medically necessary when ALL the following criteria are met:</b></p> <ul style="list-style-type: none"> <li>• One or more is present: <ul style="list-style-type: none"> <li>○ Joint pain</li> <li>○ Locking</li> <li>○ Pain with range of motion (ROM)</li> <li>○ Limited ROM</li> <li>○ Crepitus (crackling or crunching sounds in a joint)</li> <li>○ Joint effusion (accumulation of fluid) or swelling</li> </ul> </li> </ul> <p><b>AND</b></p> <ul style="list-style-type: none"> <li>• Imaging or biopsy demonstrates underlying pathology consistent with the reported medical condition (e.g., synovitis, joint effusion)</li> </ul> <p><b>AND</b></p> <ul style="list-style-type: none"> <li>• Documentation of three months of failed non-operative, conservative management as demonstrated by a trial of one or more of the following medications: <ul style="list-style-type: none"> <li>○ NSAIDs</li> <li>○ Acetaminophen</li> <li>○ Intra-articular corticosteroid injection, as appropriate</li> </ul> </li> </ul> <p><b>AND</b></p> <ul style="list-style-type: none"> <li>• A trial of the following physical measures: <ul style="list-style-type: none"> <li>○ PT and/or directed home exercise for at least 6 weeks</li> </ul> </li> </ul> <p><b>AND</b></p>



Indication	Medical Necessity
	<ul style="list-style-type: none"> <li>• Confirmed diagnosis of one of the following conditions:               <ul style="list-style-type: none"> <li>○ Inflammatory arthritis (rheumatoid arthritis, gout, psoriatic arthritis, pseudogout)</li> <li>○ Hemochromatosis (iron overload)</li> <li>○ Hemophilia</li> <li>○ Lyme synovitis</li> <li>○ Non-specific synovitis (e.g., proliferative synovitis, post operative synovitis from shoulder replacement, etc.)</li> <li>○ Pigmented villonodular synovitis (PVNS)- (rare condition of overgrowth of cells within the synovial tissue)</li> <li>○ Recurrent hemarthrosis (joint bleeding) secondary to sickle cell anemia, or bleeding diathesis (excessive bleeding)</li> <li>○ Synovial chondromatosis (a rare condition where cartilage nodules develop within the synovium)</li> </ul> </li> </ul>

Procedure	Not Medically Necessary
<b>Other indications or situations</b>	<b>All indications not listed or other situations not described above, including when policy criteria are not met, are considered not medically necessary.</b>

Documentation Requirements
<p><b>The patient’s medical records submitted for review for all conditions should document that medical necessity criteria are met. The record should include the following:</b></p> <p><b>For shoulder arthroscopy repair of acromioclavicular (AC) separation documentation should support ALL the following:</b></p> <ul style="list-style-type: none"> <li>• One or more of the following symptoms is documented:           <ul style="list-style-type: none"> <li>○ Recent traumatic event</li> <li>○ Shoulder pain</li> <li>○ Deformity</li> </ul> </li> </ul> <p><b>AND</b></p> <ul style="list-style-type: none"> <li>• Rockwood type III or higher rated injury (see <a href="#">Related Information</a>) diagnosed by imaging           <ul style="list-style-type: none"> <li>○ Preferred x-ray</li> </ul> </li> </ul>



## Documentation Requirements

- Acceptable alternatives include MRI if soft tissue assessment is needed or x-ray in inconclusive, ultrasound is not typically used for grading AC separation.

### **For shoulder arthroscopy repair of decompression of subacromial space for acromioplasty for rotator cuff tendonitis documentation should support ALL the following:**

- History of disabling shoulder pain with loss of shoulder function which interferes with activities of daily living (ADLs)

#### **AND**

- At least ONE of the following positive orthopedic tests (see [Related Information](#)) on physical exam compared to the non-affected shoulder
  - Hawkins-Kennedy Impingement Test
  - Neer Impingement Test

#### **AND**

- Documentation of three months of failed non-operative, conservative management as demonstrated by a trial of one or more of the following medications:
  - NSAIDs
  - Acetaminophen
  - Subacromial corticosteroid injection, as appropriate

#### **AND**

- A trial of the following physical measures:
  - PT and/or directed home exercise for at least 6 weeks

#### **AND**

- Plain x-rays or imaging (MRI or CT) demonstrate findings consistent with subacromial impingement, (e.g., Type II or III acromions)

### **For shoulder arthroscopy repair of a full thickness rotator cuff documentation should support ALL the following:**

History of disabling shoulder or upper arm pain with loss of shoulder function which interferes with ADLs, and

- Shoulder pain or weakness on resisted abduction or rotation, and
- Tenderness over rotator cuff

#### **AND**

- One of the following positive orthopedic tests is present
  - Drop arm test
  - Painful arc test
  - Empty can test (aka Jobe test)
  - Weakness of external rotation (lag/dropping sign)



## Documentation Requirements

### AND

- Imaging demonstrates partial or full-thickness rotator cuff tear

### AND

- Documentation of three months of failed non-operative, Documentation Requirements conservative management as demonstrated by a trial of one or more of the following medications:
  - NSAIDs
  - Acetaminophen
  - Subacromial corticosteroid injection, as appropriate

### AND

- A trial of the following physical measures:
  - PT and/or directed home exercise for at least 6 weeks

### For shoulder arthrotomy of resection of distal clavicle for AC joint arthritis documentation should support ALL the following:

- History of disabling shoulder pain with loss of shoulder function which interferes with ADLs

### AND

- Localized tenderness to palpation of the AC joint

### AND

- At least one of the following positive orthopedic tests on physical exam compared to the non-affected shoulder
  - Cross-Body Adduction Test (aka Scarf Test, Cross-Over Adduction Test)
  - Resisted AC Joint Extension Test

### AND

- Documentation of three months of failed non-operative, conservative management as demonstrated by a trial of one or more of the following medications:
  - NSAIDs
  - Acetaminophen
  - AC joint corticosteroid injection, as appropriate

### AND

- A trial of the following physical measures:
  - PT and/or directed home exercise for at least 6 weeks

### AND

- Plain x-rays or imaging (MRI or CT) demonstrate findings consistent with AC joint arthritis

### For shoulder arthrotomy repair of initial shoulder dislocation documentation should support ALL the following:



## Documentation Requirements

- History of shoulder dislocation or subluxation with disabling shoulder pain and loss of shoulder function which interferes with ADLs, and
- Instability found on physical exam demonstrated by any of the following positive orthopedic tests/signs
  - Anterior or posterior apprehension test
  - Load and shift test
  - Sulcus sign, and
- MRI findings demonstrate at least ONE of the following
  - A labral lesion consistent with clinical instability (e.g., Bankart lesion)
  - Hill-Sachs lesion
  - Capsular tear (thickening and edema of the joint)
  - Capsular redundancy with clinical multidirectional instability (shoulder joint capsule is loose or stretched)

### AND

- Documentation of three months of failed non-operative, conservative management as demonstrated by a trial of one or more of the following medications:
  - NSAIDs
  - Acetaminophen
  - Intra-articular corticosteroid injection

### AND

- A trial of the following physical measures:
  - PT and/or directed home exercise for at least 6 weeks

### For shoulder arthroscopy for synovectomy (major or complete) documentation should support ALL the following:

- One or more of the following symptoms is present:
  - Joint pain
  - Locking
  - Pain with ROM
  - Limited ROM
  - Crepitus (crackling or crunching sounds in a joint)
  - Joint effusion (accumulation of fluid) or swelling

### AND

- Imaging or biopsy demonstrates underlying pathology consistent with the reported medical condition (e.g., synovitis, joint effusion)

### AND



## Documentation Requirements

- Documentation of three months of failed non-operative, conservative management as demonstrated by a trial of one or more of the following medications:
  - NSAIDs
  - Acetaminophen
  - Intra-articular corticosteroid injection, as appropriate

### AND

- A trial of the following physical measures:
  - PT and/or directed home exercise for at least 6 weeks

### AND

- Diagnosis of ONE of the following conditions is present:
  - Inflammatory arthritis (rheumatoid arthritis, gout, psoriatic arthritis, pseudogout)
  - Hemochromatosis (iron overload)
  - Hemophilia
  - Lyme synovitis
  - Non-specific synovitis (e.g., proliferative synovitis, post operative synovitis from shoulder replacement, etc.)
  - Pigmented villonodular synovitis (PVNS)- (rare condition of overgrowth of cells within the synovial tissue)
  - Recurrent hemarthrosis (joint bleeding) secondary to sickle cell anemia, or bleeding diathesis (excessive bleeding)
  - Synovial chondromatosis (a rare condition where cartilage nodules develop within the synovium)

## Coding

Code	Description
<b>CPT</b>	
23105	Arthrotomy; glenohumeral joint, with synovectomy, with or without biopsy (glenohumeral synovectomy)
23106	Arthrotomy; sternoclavicular joint, with synovectomy, with or without biopsy (sternoclavicular synovectomy)
23120	Claviclectomy, partial (partial clavicle resection)
23130	Acromioplasty or acromionectomy, partial, with or without coracoacromial ligament release



Code	Description
23410	Repair of ruptured musculotendinous cuff (e.g., rotator cuff) open, acute
23412	Repair of ruptured musculotendinous cuff (e.g., rotator cuff) open chronic
23420	Reconstruction of complete shoulder (rotator) cuff avulsion, chronic (includes acromioplasty)
23450	Capsulorrhaphy, anterior; Putti-Platt procedure or Magnuson type operation
23455	Capsulorrhaphy, anterior; with labral repair (e.g., Bankart procedure)
23460	Capsulorrhaphy, anterior, any type; with bone block
23462	Capsulorrhaphy, anterior, any type; with coracoid process transfer
23465	Capsulorrhaphy, glenohumeral joint, posterior, with or without bone block
23466	Capsulorrhaphy, glenohumeral joint, any type multi-directional instability
23550	Open treatment of acromioclavicular dislocation, acute or chronic
23552	Open treatment of acromioclavicular dislocation, acute or chronic; with fascial graft (includes obtaining graft)
23660	Open treatment of acute shoulder dislocation (open shoulder dislocation reduction)
23670	Open treatment of shoulder dislocation, with fracture of greater humeral tuberosity, includes internal fixation, when performed
23680	Open treatment of shoulder dislocation, with surgical or anatomical neck fracture, includes internal fixation, when performed
23929	Unlisted procedure, shoulder

**Note:** CPT codes, descriptions and materials are copyrighted by the American Medical Association (AMA). HCPCS codes, descriptions and materials are copyrighted by Centers for Medicare Services (CMS).

## Related Information

### Definition of Terms

**Acromioplasty:** is a type of shoulder surgery where a portion of the acromion bone is removed to relieve pressure on the rotator cuff by creating more space for tendon movement, which reduces pain and inflammation caused by any impingement in the area.



**Anterior Apprehension Test:** is a test used to assess anterior instability of the shoulder. An individual lies supine and their arm is abducted to 90 degrees. The arm is slowly rotated pushing the humeral head forward (anteriorly). A positive test is indicated by a sense of impending dislocation of the shoulder.

**Anterior glenoid rim fracture:** is a break at the front edge of glenoid cavity (shoulder socket) often resulting from traumatic shoulder dislocation and associated with joint instability.

**Bankart lesion:** is a tear of anteroinferior glenoid labrum (cartilage rim at front of shoulder socket), typically resulting from anterior shoulder dislocation and associated with recurrent joint instability.

**Capsulorrhaphy:** is a surgical procedure that stabilizes a loose or unstable shoulder joint by tightening the shoulder capsule (the tissue surrounding the joint) and ligaments, reducing the space around the joint, to prevent excessive movement. It is usually done to address shoulder instability or dislocations. It may be performed through an open surgical technique or arthroscopically.

#### **Cofield Classification of Full-Thickness Rotator Cuff Tears:**

- **Small:** Less than 1 cm
- **Medium:** 1-3 cm
- **Large:** 3-5 cm
- **Massive:** Greater than 5 cm

**Crank Test:** (aka Passive Compression Test, Labral Crank Test) is a test used to assess for glenoid labral tears, particularly SLAP tears, in the shoulder. It involves applying compression to the shoulder of an individual either seated or lying supine with the affected arm abducted to 90 degrees with the elbow flexed to 90 degrees while rotating the humerus. The test is considered positive if pain or clicking associated with a labral tear is reproduced with this maneuver.

**Cross-Body Adduction Test:** (aka Scarf Test, Cross-Over Adduction Test) is a test used to assess potential injuries to the acromioclavicular (AC) joint. It involves passively adducting an individual's arm across the body, compressing the AC joint. A positive test produces pain, possibly indicating AC joint arthritis or subluxation.

**Drop arm test:** is a test used to identify a significant rotator cuff tear, particularly of the supraspinatus muscle. The individual is seated or standing. The examiner lifts the individual's affected arm out to the side (abducts it) to 90 degrees while supporting the arm at the elbow. The examiner then removes their arm of support. The test is considered positive if the arm drops suddenly without support or if the individual cannot hold the arm in the 90-degree position or cannot control a smooth, slow descent. A positive test is indicative of a full-thickness rotator cuff tear.



## **Ellman Classification of Partial-Thickness Rotator Cuff Tears**

- **Grade 1:** Less than 3 mm deep
- **Grade 2:** 3-6 mm deep
- **Grade 3:** Greater than 6 mm deep

**Empty can test:** (aka Jobe test) is a test used to assess the function of the supraspinatus muscle in the shoulder. The individual stands with their arms at their sides. The individual raises both arms to 90 degrees abduction with their palms facing forward. The individual internally rotates their arms so that their thumbs point towards the floor (like they are emptying a can). The examiner applies downward pressure on the individual's arms, asking them to resist. A test is considered positive when there is pain in the shoulder, weakness or instability to resist the downward pressure, or dropping of the affected arm. A positive test is indicative of a supraspinatus injury such as a tear, rotator cuff impingement, or nerve damage.

**Hawkins-Kennedy impingement test:** is a test used to assess for subacromial impingement syndrome in the shoulder. An individual's arm while they are standing or seated is passively internally rotated while it is flexed to 90 degrees with the elbow flexed to 90 degrees. A positive test is when this maneuver reproduces pain.

**Hill-Sachs lesion:** is a compression fracture of the humeral head (the ball of the shoulder joint) that occurs when the shoulder dislocates. It occurs when the humerus slips out of the shoulder socket and the humeral head slides forward and compresses the glenoid rim, creating a divot or indentation in the bone, which causes pain and limited arm movement.

**Load and Shift test:** is a test used to assess the stability of the glenohumeral joint (shoulder joint). An individual is usually seated with their arm relaxed. The examiner stabilizes the scapula and clavicle with one hand and grasps the humeral head with the other hand and guides it into a neutral position within the glenoid. The examiner applies a gentle pressure to the humeral head either anteriorly (pushing forward) or posteriorly (pushing backward) to assess the joint stability in those directions (the load phase). For the shift phase, the examiner guides the humeral head within the glenoid fossa (glenoid cavity). The movements on the affected side are compared to the other healthy shoulder. The test is considered positive if pain or instability is reproduced during the movements.

**Neer impingement test:** is a test used to assess the presence of subacromial impingement syndrome. An examiner passively flexes an individual's arm forward while internally rotating it with the thumb facing down, all while stabilizing the scapula. A positive test is indicated when pain is reproduced in the shoulder, suggesting impingement of the supraspinatus tendon, long head of the biceps tendon, or subacromial bursa.



**Painful arc test:** identifies subacromial impingement syndrome in the shoulder suggesting irritation of the rotator cuff tendons or subacromial bursa. The individual sits or stands with their arms at their sides. The individual is instructed to slowly abduct their arm in the scapular plane with their thumb pointing upwards. A test is considered positive if pain is present when the arm is abducted to around 60 degrees and resolves after around 120 degrees of abduction. When the individual slowly brings their arm down again (adduction), the pain should reappear at the same arc. There should be no pain felt during the initial and final parts of the movement. The test is indicative of impingement syndrome of the supraspinatus tendon.

**Posterior Apprehension test:** is a test used to assess posterior shoulder instability. An individual lies supine or sits upright and their arm is abducted to 90 degrees with the elbow bent at 90 degrees. A slight pressure is applied to the humerus, pushing down on the elbow while simultaneously adducting (moving towards the body) and internally rotating the arm. The test is considered positive with a sense of the humeral head moving out of place posteriorly.

**Resisted AC Joint Extension test:** (aka the AC resisted extension test) is a test used to assess for problems in the AC joint, such as arthritis or ligament injuries. An individual is seated with their arm flexed to 90 degrees and internally rotated with the elbow flexed to 90 degrees. The examiner applies resistance to the individual's arm as the individual attempts to extend their arm horizontally away from their body. The test is considered positive if the individual experiences pain near the AC joint during the resisted movement.

#### **Rockwood classification of AC injuries:**

**Type I:** Minor sprain of the acromioclavicular ligament; intact joint capsule; intact coracoclavicular ligament; intact deltoid and trapezius

**Type II:** Rupture of the acromioclavicular ligament and joint capsule; sprain of the coracoclavicular ligament but intact coracoclavicular interspace; minimal detachment of the deltoid and trapezius

**Type III:** Rupture of the acromioclavicular ligament, joint capsule, and coracoclavicular ligament; elevated clavicle (100% or less displacement); detachment of the deltoid and trapezius

**Type IV:** Rupture of the acromioclavicular ligament, joint capsule, and coracoclavicular ligament; posteriorly displaced clavicle into the trapezius; detachment of the deltoid and trapezius

**Type V:** Rupture of the acromioclavicular ligament, joint capsule, and coracoclavicular ligament; elevated clavicle (greater than 100% displacement); detachment of the deltoid and trapezius



**Type VI** (rare): Rupture of acromioclavicular ligament, joint capsule, and coracoclavicular ligament; the clavicle is displaced behind the tendons of the biceps and coracobrachialis.

**Shoulder dislocation:** is a displacement of the humeral head from the glenoid fossa of the scapula, resulting in loss of normal articulation within the glenohumeral joint.

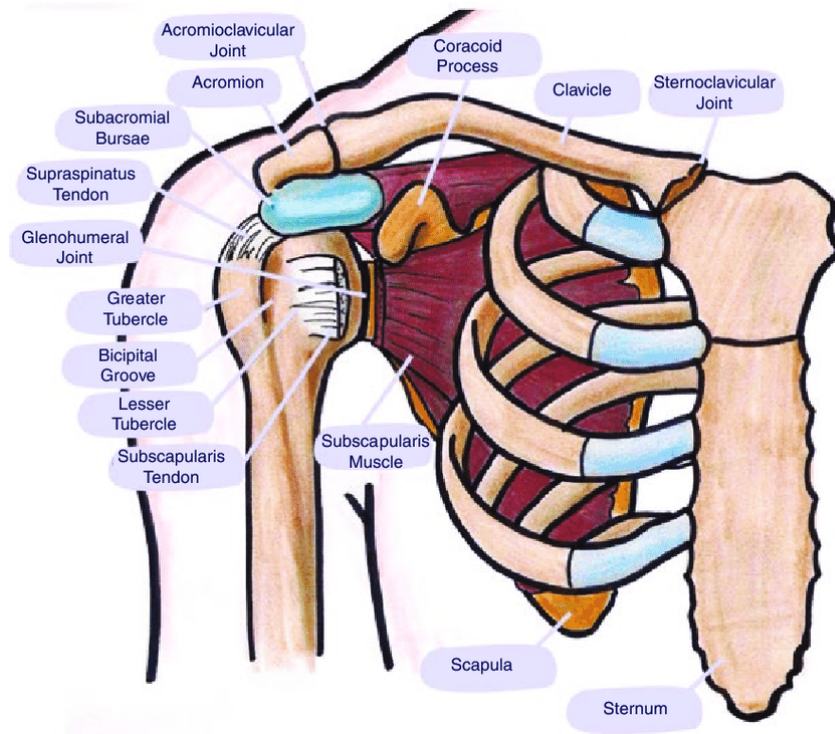
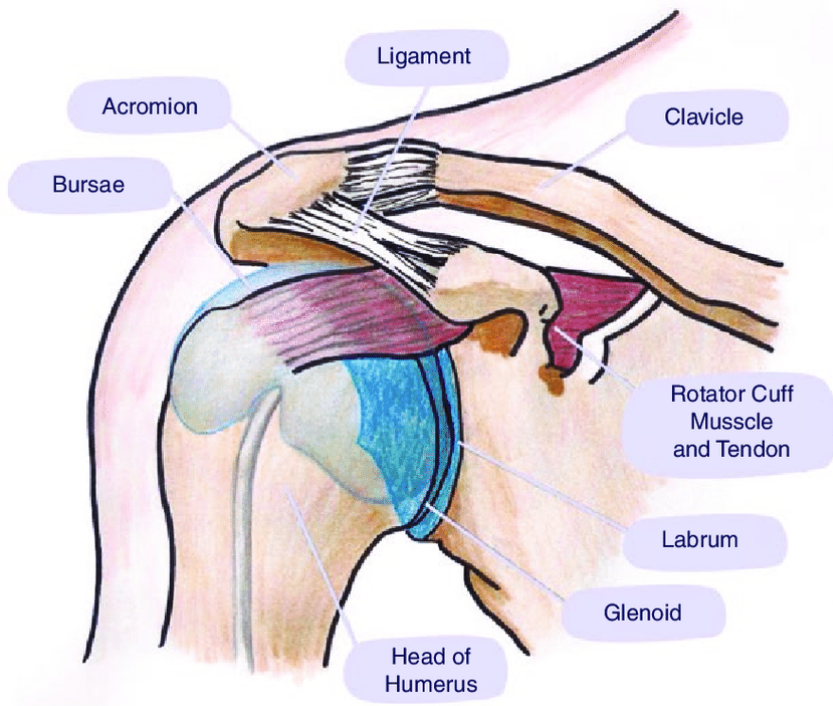
**Shoulder subluxation:** is a partial dislocation of the shoulder joint, where the head of the upper arm bone (humerus) slips out of the shoulder socket (glenoid) but does not completely dislocate. This condition may be caused by traumatic injuries such as a fall or a direct blow to the shoulder, or from non-traumatic causes like repetitive movements that occur during sports. Symptoms may include pain, looseness or instability in the shoulder, limited range of motion, and possibly a popping or clicking sensation. It is less severe than full dislocation. It may resolve on its own, be treated with conservative care, or require surgery to repair damaged tissues.

**Subacromial decompression:** is a surgical procedure used to treat shoulder impingement where the tendons and bursa become compressed, causing pain and limited movement. The procedure increases room in the subacromial space by removing bone spurs or inflamed tissue, allowing the tendons and bursa to move more freely. The procedure can be performed with an open surgical technique or arthroscopically.

**Sulcus sign:** is a test used to assess inferior shoulder instability, such as a laxity or subluxation of the glenohumeral joint in the inferior direction (downwards). An individual is seated or standing with their arm relaxed at their side. The examiner stabilizes the shoulder and grasps the individual's forearm or elbow and then pulls the arm downwards. The test is considered positive if there is the appearance of a visible, palpable groove or depression (the "sulcus") below the acromion (the bony prominence at the top of the shoulder) as the humeral head pulls away from the shoulder socket.

**Synovectomy:** is an open surgical excision of inflamed synovial tissue from the glenohumeral joint, typically indicated for chronic synovitis unresponsive to conservative treatment. Procedures may include open glenohumeral synovectomy, subacromial synovectomy, or posterior capsular synovectomy.





Source: [https://www.researchgate.net/figure/Anatomy-of-the-shoulder-joint\\_fig5\\_348256306](https://www.researchgate.net/figure/Anatomy-of-the-shoulder-joint_fig5_348256306). Accessed August 21, 2025



### Description

Shoulder arthrotomy refers to a surgical incision into the glenohumeral joint, typically performed as part of open procedures for diagnostic exploration, removal of intra-articular loose bodies, or treatment of structural instability. While arthroscopic techniques are preferred for many shoulder conditions, open procedures involving arthrotomy are for select non-emergent cases, particularly when anatomical complexity, failed prior surgery, or surgeon expertise favor an open approach. Open shoulder procedures involving arthrotomy may be appropriate across age groups but are most commonly indicated in adolescents and young adults, particularly males under 30, who have high recurrence risk, failed prior stabilization, or significant bone loss.

### Background

Shoulder instability is a common orthopedic condition, particularly among young, active individuals. It refers to the inability of the glenohumeral joint to maintain its normal alignment, often due to trauma, ligamentous laxity, or repetitive overhead activity. Instability may present as subluxation, dislocation, or a sensation of the shoulder "giving way," and can lead to chronic pain, functional impairment, and progressive joint damage if left untreated. The incidence of shoulder dislocation in the United States is approximately 23.9 per 100,000 person-years, with higher rates in young males aged 15 to 29.<sup>1</sup> Between 60% and 91.3% of all shoulder dislocations occur in males, with a male-to-female ratio of 2.6:1.<sup>1</sup> Shoulder instability affects approximately 2% of the general population. Among individuals who experience a dislocation before age 20, the recurrence rate is as high as 80%, compared to 20% in those over age 40.<sup>2</sup>

Open shoulder procedures, particularly arthrotomy, remain critical in complex, high-risk, or revision cases where precise anatomical restoration is required. By providing direct visualization of intra-articular structures such as the capsule, labrum, and glenoid rim, arthrotomy enables secure repair in scenarios involving large bony defects, extensive cartilage injury, or failed prior stabilization. Techniques like the Latarjet (used for recurrent shoulder locations with significant bone loss) and open Bankart repair (used to restore shoulder stability after recurrent anterior dislocations) employ arthrotomy and are well-supported in the literature as effective

interventions for recurrent anterior instability and structural compromise. These approaches are especially valuable when arthroscopic methods prove insufficient. In non-urgent cases, clinical guidelines recommend a stepwise treatment strategy beginning with physical therapy, pharmacologic management, and activity modification before progressing to surgical intervention.

Open shoulder procedures show superior performance in both elderly and high-demand populations. High-risk populations include contact athletes such as football and wrestling players, overhead athletes such as baseball and volleyball players, military personnel, manual laborers, and individuals with generalized ligamentous laxity or connective tissue disorders. Open procedures involving arthrotomy are most often medically necessary in young males under 30 with recurrent anterior instability and bone loss, individuals with failed prior arthroscopic stabilization, individuals with multidirectional instability unresponsive to conservative care, and individuals with intra-articular loose bodies or unexplained joint pathology requiring direct visualization.

Recurrent shoulder instability can lead to secondary intra-articular damage, including labral tears, cartilage degeneration, and bony lesions such as Hill-Sachs and glenoid defects. These structural changes often develop over time due to repeated subluxation or dislocation events and may complicate both diagnosis and treatment. Chronic instability is also associated with reduced proprioception and altered shoulder kinematics, which can impair function and increase the risk of osteoarthritis. Early recognition and appropriate intervention are essential to prevent progression and preserve joint integrity.

Open anterior shoulder stabilization should be considered primarily when critical glenoid bone loss is present, especially when recurrent shoulder dislocations occur, or when other factors like failed arthroscopic repair, engaging Hill-Sachs lesions, additional shoulder pathologies, and high likelihood of instability increase the risk of recurrent instability. These criteria help surgeons select individuals who are most likely to benefit from durable outcomes with open procedures.<sup>3</sup>

## Summary of Evidence

### Rotator Cuff Tears

A systematic review of the literature by Mohammed et. al., (2021) discussing the relevance of open rotator cuff repair concluded that the open rotator cuff repair is advantageous for larger tears and the increased ease of repair. The author summarizes that an open repair is preferred in these situations over an arthroscopic approach: L shaped tears, which are significantly longer medial to lateral as compared to anterior to posterior, massive and large tears, complete tear of



the subscapularis, poor tissue quality and extensive lamination, previously failed arthroscopic revision repairs, reconstruction of the superior capsule with long head of biceps in conjunction with a partial repair of a massive rotator cuff tear.<sup>4</sup>

A prospective cohort study by Zarezadeh et al., (2020) comparing clinical outcomes between open and arthroscopic rotator cuff repair in individuals with rotator cuff repair were followed for 3 years. The mean tear size in both surgical groups were similar, and all individuals improved in pain, active abduction, active forward flexion, and function. The open surgery group showed superior outcomes in 44% increased function over the arthroscopic surgery group at the follow up.<sup>5</sup>

An Austin Orthopedic Institute (2025) report emphasized that while arthroscopy offers shorter recovery times and less postoperative pain, open surgery provides better access and precision for complex repairs, such as total shoulder replacements and extensive rotator cuff tears. Open procedures remain essential for anatomical correction and structural durability in high-demand or revision cases.<sup>6</sup>

## **Shoulder Dislocation Stabilization**

Open shoulder procedures involving arthrotomy are supported by a substantial body of evidence, including randomized controlled trials (RCTs), systematic reviews, and long-term cohort studies. These procedures remain essential in the management of recurrent anterior instability, multidirectional instability (MDI), intra-articular pathology, and failed prior repairs—particularly in high-risk or anatomically complex cases. A 15-year prospective RCT by Bottoni et al. compared open and arthroscopic anterior stabilization and found no significant difference in long-term recurrence or functional outcomes. However, individuals with “off-track” Hill-Sachs lesions had significantly higher failure rates, highlighting the importance of glenoid track assessment and the potential need for open procedures in cases of substantial bone loss (Bottoni et al., 2021).<sup>7</sup>

Shoulder arthrotomy remains a clinically validated intervention for managing complex glenohumeral pathology in adult populations, particularly in cases involving recurrent instability, glenoid bone loss, multidirectional laxity, and revision scenarios. Meta-analyses and randomized controlled trials (Hurley 2019; Bottoni 2021) consistently report lower recurrence rates, higher return-to-sport percentages, and sustained satisfaction in open procedures versus arthroscopy:<sup>7, 8</sup> Hurley et al. conducted a systematic review and meta-analysis comparing open and arthroscopic Latarjet procedures. Both approaches demonstrated similar rates of recurrent instability and complications, but open procedures were associated with lower rates of



persistent apprehension in some subgroups, suggesting a role for open techniques in individuals with high functional demands or failed prior stabilization (Hurley et al., 2019).<sup>8</sup>

Gao et al. (2020) reviewed multiple RCTs on Bankart repair (used to restore shoulder stability after recurrent anterior dislocations) and concluded that recurrence rates in arthroscopic cases remained static over time, while open Bankart procedures maintained superior outcomes in contact athletes and revision scenarios. Gao et al. concluded that open Bankart repair remains a viable and effective option, particularly in high-risk individuals or those with failed arthroscopic repairs. Despite the increasing use of arthroscopy, open procedures continue to yield favorable outcomes in appropriately selected individuals.<sup>9</sup> Harris et al. (2021) synthesized 26 studies totaling 1,781 individuals and found recurrence rates of 8% for open stabilization versus 11% for arthroscopic methods. The return-to-sport rate was significantly higher in the open group (89% vs. 74%), suggesting superior biomechanical durability.<sup>10</sup>

In high-demand populations such as overhead athletes and military personnel, open procedures have demonstrated superior durability. A retrospective cohort study with 106 athletes under age 30 years undergoing an open Latarjet procedure for anterior shoulder instability by Bavarel et al. (2018), showed net improvement of 27.95 in Rowe score (postoperative assessment of shoulder stability, motion, and function on a scale of maximum score 100) in the competitive athletes with a 14.5% improvement in the recreational athletes in a mean follow up of 46 months. The repair was durable and 100% of all participants resumed their previous sport at an identical or an increased level prior to their shoulder injury. The open Latarjet is concluded to be considered as the primary choice for shoulder stabilization for the highly active populations including athletes to allow for higher functional demands and to reduce the greater risks of dislocation possible in an arthroscopic repair.<sup>11</sup>

Mohtadi et al., (2014) reported that for open and arthroscopic repair for shoulder stabilization in a 1:1 randomized controlled trial with 196 individuals, at two years there was no difference between open and arthroscopic repair for quality of life. However, there was a significant difference in recurrence rates of dislocation, with 52% less recurrence of shoulder instability in the open shoulder repair group at two years compared to the arthroscopically repaired shoulder instability. This data suggests that an open surgical repair for shoulder instability is recommended to reduce the recurrence risk of instability in younger males with a Hills-Sachs lesion.<sup>12</sup>



## Open Capsular Shift

A systematic review by Jacobsen et al., (2012) with a total of 197 individuals who had open capsular shift surgery, or to arthroscopic capsular plication, concluded that in the case of either traumatic or atraumatic shoulder instability onset in 2 directions in the absence of structural lesions, similar results are seen with either open or arthroscopic surgery when examining the recurrence of instability, complications, loss of external rotation, and return to sport. Both procedures were demonstrated to be dependable and safe with minimal complications.<sup>13</sup>

A systematic review by Huerta et al., (2017) examining management of shoulder instability and comparing open vs. arthroscopic procedures in the setting without bone loss, showed similar outcomes for both procedures. The authors state that if the glenoid bone loss is greater than 25%, the open procedure is the superior choice for repair.<sup>14</sup>

## Subacromial Decompression

An open subacromial decompression procedure is preferred in severe cases which need a bigger incision to directly access the shoulder joint, especially with large rotator cuff tears or in the case of shoulder damage presenting as higher complexity.<sup>15</sup> In a prospective randomized study by Farfaras et al., (2014) of 87 individuals with subacromial impingement syndrome, the study compared open and arthroscopic acromioplasty with physiotherapy. The open acromioplasty group demonstrated the greatest improvement over the follow up at three years.<sup>16</sup>

## Ongoing and Unpublished Clinical Trials

Table 1. Summary of Key Trials

NCT No.	Trial Name	Planned Enrollment	Completion Date
<b>Ongoing</b>			
<a href="#">NCT06360887</a>	Management of Proximal Humerus Fractures in Elderlies: a Clinical Trial	351	Jan 2028
<a href="#">NCT07520669</a>	Does Capsuloplasty Reduce External Rotation After Coracoid Impingement? A Randomized Controlled Trial	104	Dec 2028



NCT No.	Trial Name	Planned Enrollment	Completion Date
<a href="#">NCT04809064</a>	Open Versus Arthroscopic Stabilization of Shoulder Instability with Subcritical Bone Loss: the OASIS Trial	400	Sep 2027
<a href="#">NCT05705479</a>	Shoulder Instability Trial Comparing Arthroscopic Stabilization Benefits Compared with Latarjet Procedure Evaluation	114	May 2027
<a href="#">NCT05807854</a>	Treatment of Degenerative Massive Rotator Cuff Tears: a Multicenter, Randomized Comparative Surgical Trial [reverse shoulder arthroplasty (RSA) vs. rotator cuff repair (RCR)]	160	March 2027

NCT: national clinical trial.

<sup>a</sup> Denotes industry-sponsored or cosponsored trial.

## Practice Guidelines and Position Statements

Guidelines or position statements will be considered for inclusion if they were issued by, or jointly by, a US professional society, an international society with US representation, or National Institute for Health and Care Excellence (NICE). Priority will be given to guidelines that are informed by a systematic review, include strength of evidence ratings, and include a description of management of conflict of interest.

## American Academy of Orthopaedic Surgeons (AAOS)

The American Academy of Orthopaedic Surgeons (AAOS) has issued a strong recommendation in 2025 that supports open surgical procedures, including arthrotomy, for managing rotator cuff repairs. The AAOS stated that there is not a difference in patient reported outcomes between open or arthroscopic procedures.<sup>17</sup>

## Medicare National Coverage

There is no national coverage determination.



## Regulatory Status

Shoulder arthroscopy is a surgical procedure and as such, is not subject to regulation by the FDA.

## References

1. Tennent DJ, Posner MA, Cameron KL. Epidemiology of shoulder instability: incidence, risk factors, and prevention of instability in the athlete. In: Musculoskeletal Key. Available from: <https://musculoskeletalkey.com/epidemiology-of-shoulder-instability-incidence-risk-factors-and-prevention-of-instability-in-the-athlete/>. Accessed on September 22, 2025.
2. Kuiper SD. The unstable shoulder. Louisville Orthopaedic Clinic. 2019. Available from: <https://www.louortho.com/blog/the-unstable-shoulder/>. Accessed on September 22, 2025.
3. Fares MY, Boufadel P, Daher M, Koa J, Khanna A, Abboud JA. Anterior Shoulder Instability and Open Procedures: History, Indications, and Clinical Outcomes. *Clin Orthop Surg*. 2023;15(4):521-533. doi:10.4055/cios23018. PMID: **37529197**
4. Mohammed KD, Lloyd RFW, Nagaraj C, Krishnan J. The Relevance of Open Rotator Cuff Repair in 2021. *Indian J Orthop*. 2021;55(2):433-442. Published 2021 Apr 7. doi:10.1007/s43465-020-00345-7. PMID: 33927822
5. Zarezadeh A, Deghani M, Mohammadsharifi G, Omidian A. A Comparison of the Clinical Outcomes between Arthroscopic and Open Rotator Cuff Repair in Patients with Rotator Cuff Tear: A Nonrandomized Clinical Trial. *Adv Biomed Res*. 2020;9:13. Published 2020 Apr 22. doi:10.4103/abr.abr\_226\_19. PMID: 32775306.
6. Comparing Open Surgery vs. Arthroscopic Surgery for the Shoulder - Austin Orthopedic Institute [Internet]. Austin Orthopedic Institute. 2025 [cited 2025 Sep 22]. Available from: <https://austinoi.com/blog/comparing-open-surgery-vs-arthroscopic-surgery-for-the-shoulder/>
7. Bottoni CR, Johnson JD, Zhou L, et al. Arthroscopic Versus Open Anterior Shoulder Stabilization: A Prospective Randomized Clinical Trial With 15-Year Follow-up With an Assessment of the Glenoid Being "On-Track" and "Off-Track" as a Predictor of Failure. *The American Journal of Sports Medicine*. 2021;49(8):1999-2005. doi:**10.1177/03635465211018212**. PMID: 34102075
8. Hurley ET, Lim Fat D, Farrington SK, Mullett H. Open Versus Arthroscopic Latarjet Procedure for Anterior Shoulder Instability: A Systematic Review and Meta-analysis. *Am J Sports Med*. 2019;47(5):1248-1253. doi:10.1177/0363546518759540. PMID: 29558168
9. Gao B, DeFroda S, Bokshan S, et al. Arthroscopic Versus Open Bankart Repairs in Recurrent Anterior Shoulder Instability: A Systematic Review of the Association Between Publication Date and Postoperative Recurrent Instability in Systematic Reviews. *Arthroscopy*. 2020;36(3):862-871. doi:10.1016/j.arthro.2019.10.022. PMID: 31870747
10. Harris JD, Gupta AK, Mall NA, et al. Long-term outcomes after Bankart shoulder stabilization. *Arthroscopy*. 2013;29(5):920-933. doi:10.1016/j.arthro.2012.11.010. PMID: 23395467.
11. Baverel L, Colle PE, Saffarini M, Anthony Odri G, Barth J. Open Latarjet Procedures Produce Better Outcomes in Competitive Athletes Compared With Recreational Athletes: A Clinical Comparative Study of 106 Athletes Aged Under 30 Years. *Am J Sports Med*. 2018;46(6):1408-1415. doi:10.1177/0363546518759730. PMID: 29589955
12. Mohtadi NG, Chan DS, Hollinshead RM, et al. A randomized clinical trial comparing open and arthroscopic stabilization for recurrent traumatic anterior shoulder instability: two-year follow-up with disease-specific quality-of-life outcomes. *J Bone Joint Surg Am*. 2014;96(5):353-360. doi:10.2106/JBJS.L.01656. PMID: 24599195.
13. Jacobson ME, Rigenbach M, Wooldridge AN, Bishop JY. Open capsular shift and arthroscopic capsular plication for treatment of multidirectional instability. *Arthroscopy*. 2012;28(7):1010-1017. doi:10.1016/j.arthro.2011.12.006. PMID: 22365265.



14. Huerta A, Rincón G, Peidro L, Combalia A, Sastre S. Controversies in the Surgical Management of Shoulder Instability: Open vs Arthroscopic Procedures. *Open Orthop J.* 2017;11:875-881. Published 2017 Aug 31. doi:10.2174/1874325001711010875. PMID: 28979597.
15. Mehta DP. Subacromial Decompression Surgery in San Jose [Internet]. Resilience Orthopedics. 2024 Available from: <https://www.resilienceorthopedics.com/shoulder/subacromial-decompression/#arthroscopic-vs-open-shoulder-decompression>. Accessed September 23, 2025.
16. Farfaras S, Sernert N, Hallström E, Kartus J. Comparison of open acromioplasty, arthroscopic acromioplasty and physiotherapy in patients with subacromial impingement syndrome: a prospective randomised study. *Knee Surg Sports Traumatol Arthrosc.* 2016;24(7):2181-2191. doi:10.1007/s00167-014-3416-4. PMID: 25385527.
17. American Academy of Orthopaedic Surgeons (AAOS) . AAOS Classic Guidelines Open vs. Arthroscopic Repairs [Internet]. American Academy of Orthopaedic Surgeons (AAOS) ; Available from: [https://www.orthoguidelines.org/guideline-detail?id=1882&tab=all\\_guidelines..](https://www.orthoguidelines.org/guideline-detail?id=1882&tab=all_guidelines..) Accessed September 23, 2025.

## History

Date	Comments
12/01/25	New policy, approved November 11, 2025, effective for dates of service on or after March 4, 2026, following 90-day provider notification. Add to Surgical section. Shoulder arthrotomy in adults is considered medically necessary for the indications noted when criteria are met. The following CPT codes will apply to this policy when it becomes effective March 4, 2026: 20670, 20680, 23040, 23044, 23101, 23105, 23106, 23107, 23120, 23130, 23410, 23412, 23415, 23420, 23450, 23455 , 23460, 23462 , 23465, 23466, 23550, 23552, 23585, 23615, 23616, 23630, 23660, 23670, 23680, and 23939.
06/01/26	Interim Review, approved May 12, 2026. Removed CPT codes 20680, 20670, 23040, 23044, 23101, 23107, 23415, 23585, 23615, 23616, 23630. Removed 23770 from policy; this is not a valid code and was replaced with 23680. Minor formatting corrections for clarity with no change to policy intent. Policy title changed from, "Shoulder Arthrotomy in Adults" to "Shoulder Open Procedures in Adults" to align with policy intent. Effective for dates of service on or after September 4, 2026, following 90-day provider notification. Policy statements modified conservative management to require where noted for each indication both a medication trial and failure as well as a trial and failure of physical measures for the following indications: decompression of subacromial space or acromioplasty for rotator cuff tendonitis, full thickness rotator cuff repair, resection of distal clavicle, shoulder dislocation, and synovectomy. Policy statements modified to require additional testing for the following indications: decompression of subacromial space or acromioplasty for rotator cuff tendonitis, full thickness rotator cuff repair, resection of distal clavicle, and shoulder dislocation, Policy statements deleted criteria for the following indications: acromioclavicular (AC) separation with recent traumatic event, shoulder pain, and deformity, partial thickness rotator cuff repair, removal of intra-articular osteochondral lesion or loose body, recurrent shoulder dislocation (greater than two years), recurrent shoulder dislocation



Date	Comments
	(less than two years), initial shoulder dislocation with Bankart, Hill-Sachs, or anterior glenoid rim fracture, recurrent shoulder dislocation with Bankart, Hill-Sachs, or anterior glenoid rim fracture, shoulder fracture repair, and shoulder hardware removal. Policy title changed from "Shoulder Open Procedures in Adults" to "Shoulder Open Procedures" to align with policy intent.

**Disclaimer:** This medical policy is a guide in evaluating the medical necessity of a particular service or treatment. The Company adopts policies after careful review of published peer-reviewed scientific literature, national guidelines and local standards of practice. Since medical technology is constantly changing, the Company reserves the right to review and update policies as appropriate. Member contracts differ in their benefits. Always consult the member benefit booklet or contact a member service representative to determine coverage for a specific medical service or supply. CPT codes, descriptions and materials are copyrighted by the American Medical Association (AMA). ©2026 Premera All Rights Reserved.

**Scope:** Medical policies are systematically developed guidelines that serve as a resource for Company staff when determining coverage for specific medical procedures, drugs or devices. Coverage for medical services is subject to the limits and conditions of the member benefit plan. Members and their providers should consult the member benefit booklet or contact a customer service representative to determine whether there are any benefit limitations applicable to this service or supply. This medical policy does not apply to Medicare Advantage.

